

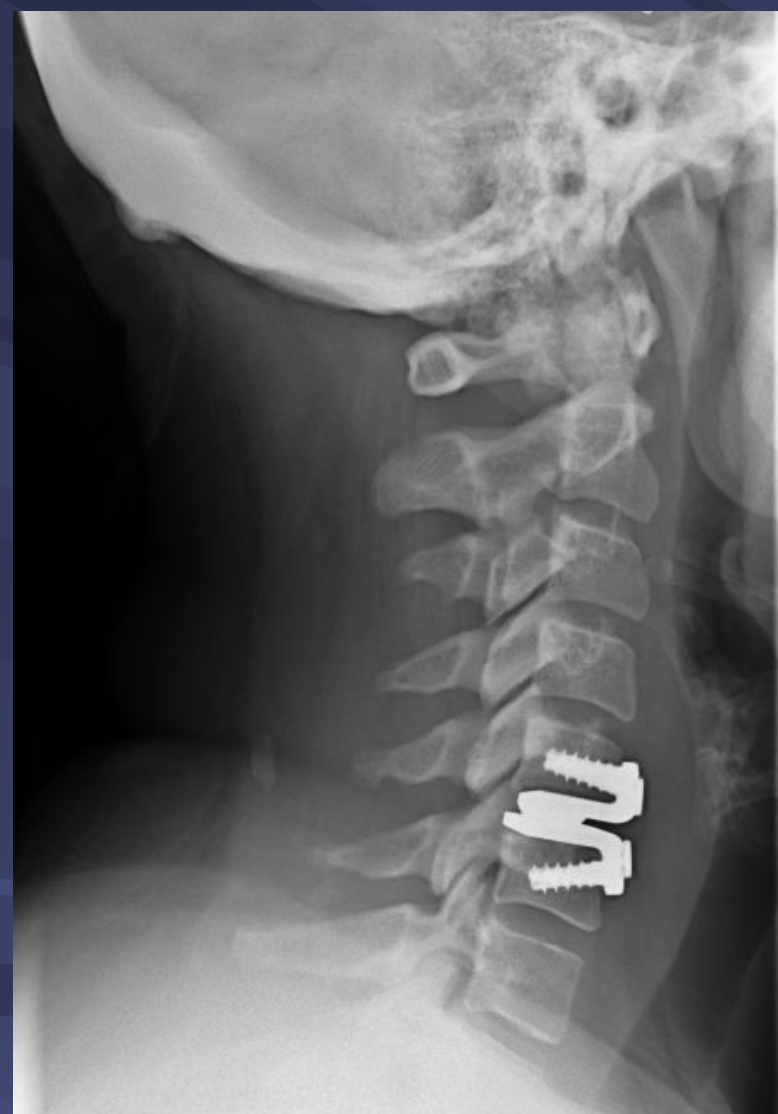Case Review:

Prestige Artificial Disc at C5/6

Robert S Pashman, MD

Scoliosis and Spinal Deformity Surgery

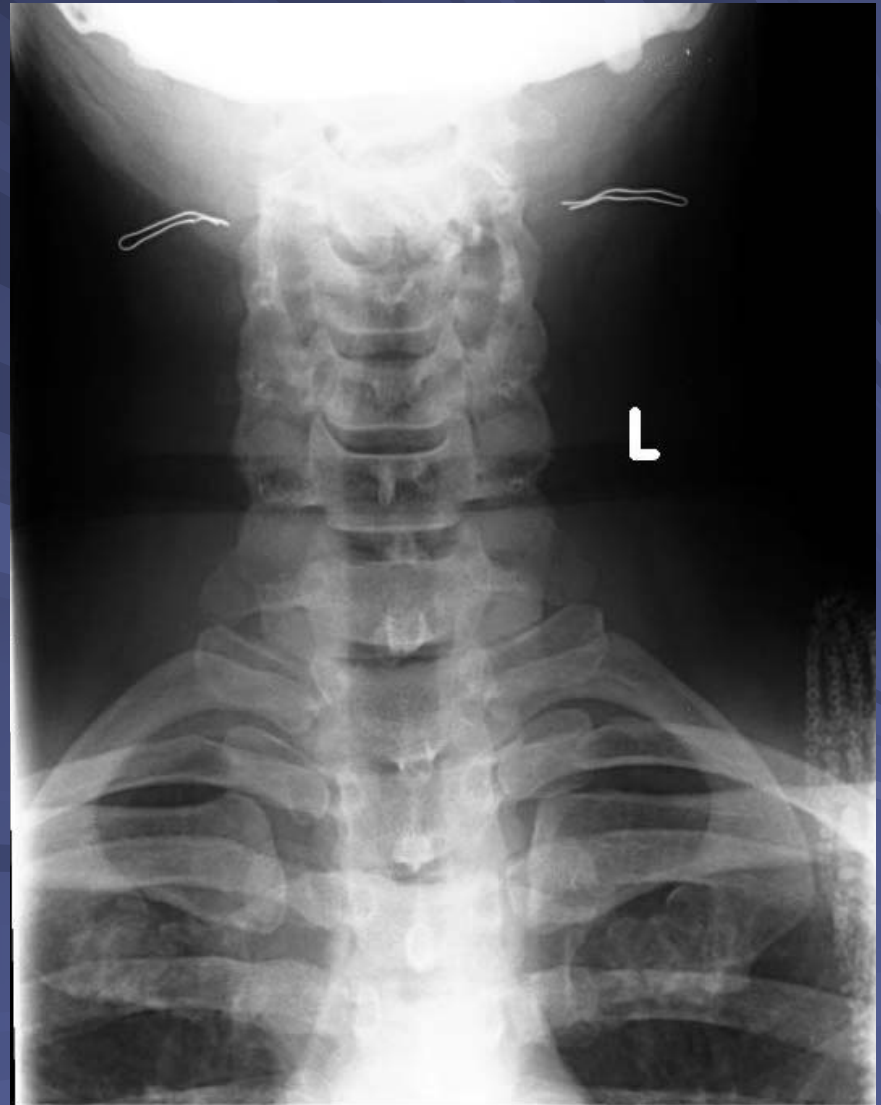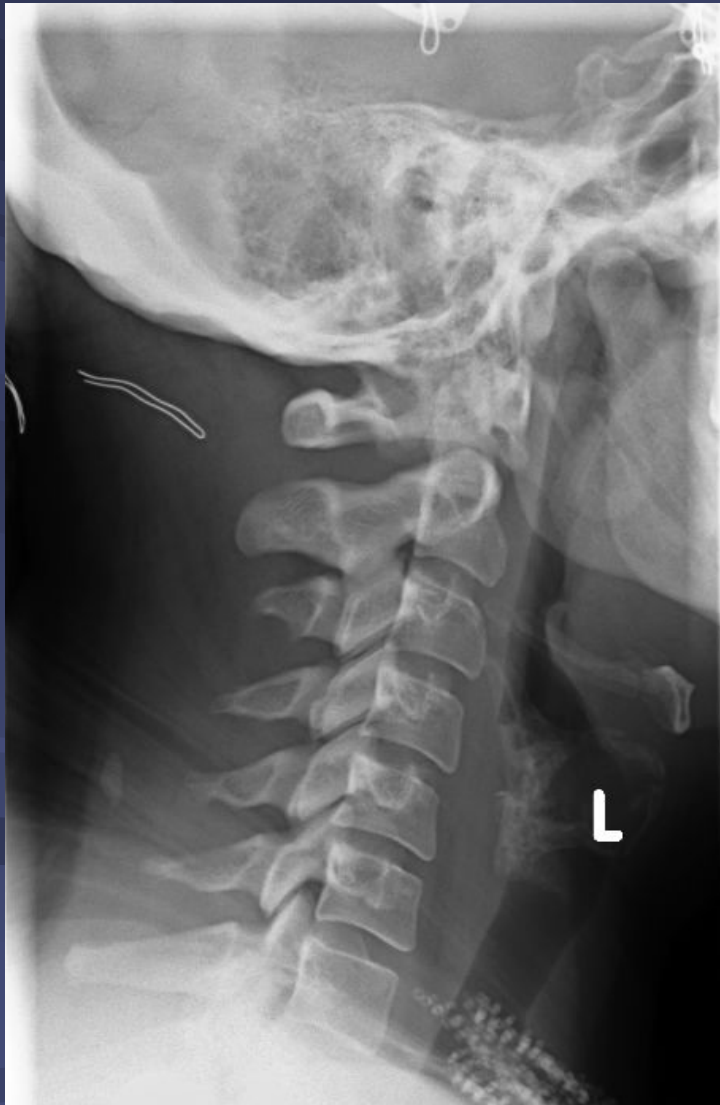www.NeckPainExplained.com



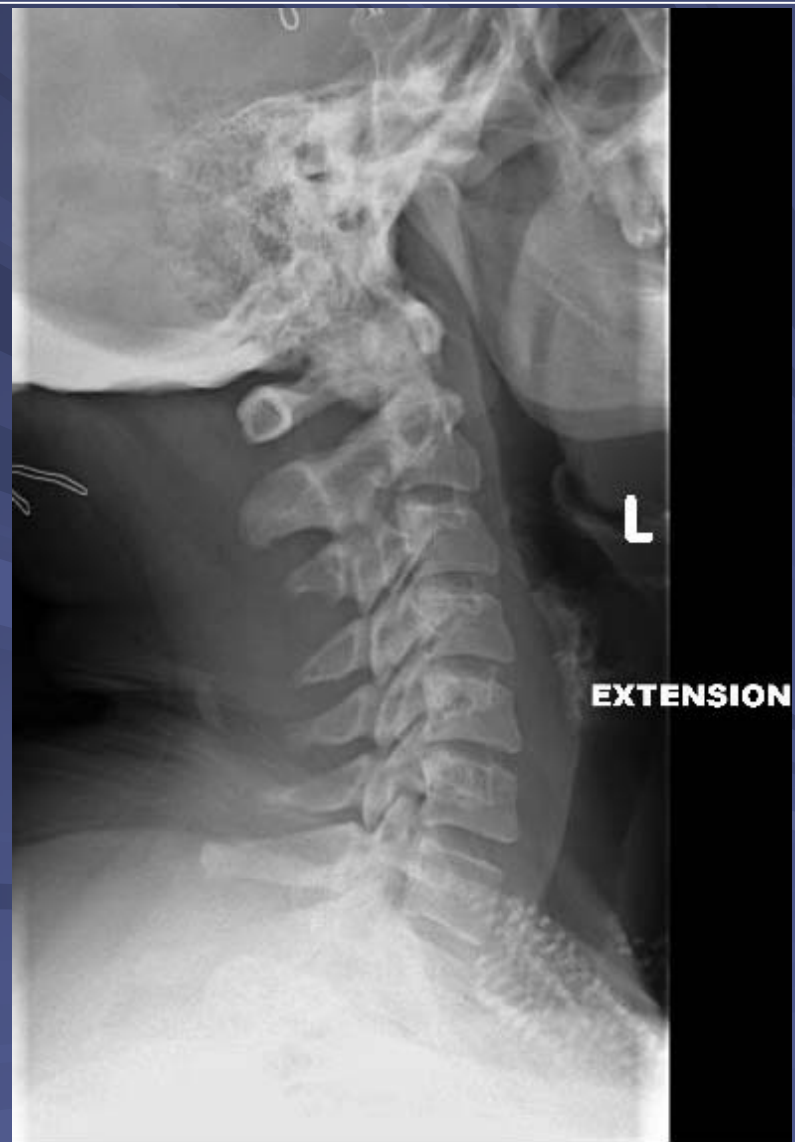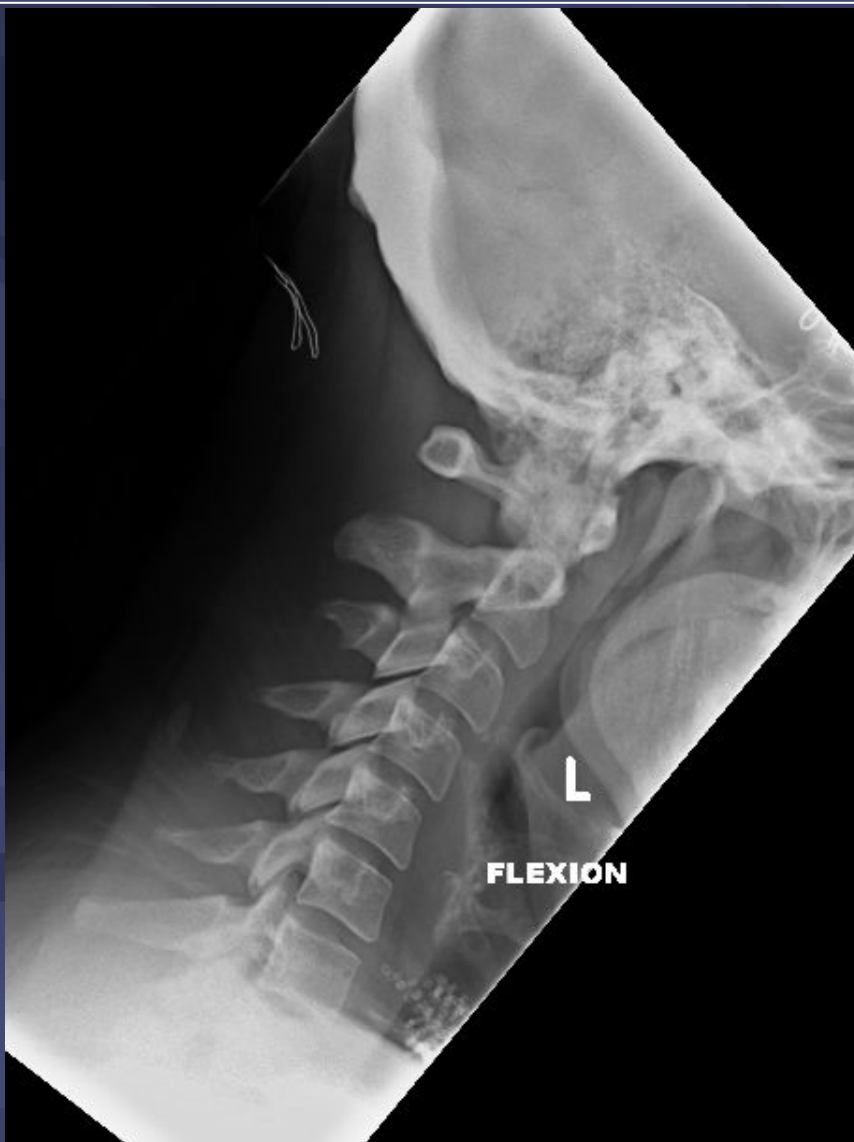Patient History

- 46 year old female
- Presented with neck pain, and numbness in both hands.
- C5-6 disc herniation with hard soft disc which on multiple MRI's show a subtle gliosis in the spinal cord, effacement of the spinal cord at this level.
- The patient has evidence of myeloradiculopathy with bilateral hand numbness, neural foraminal stenosis also.
- The patient has mild degenerative disc disease at C6-7.

Pre-op X-rays



Flexion/Extension X-rays



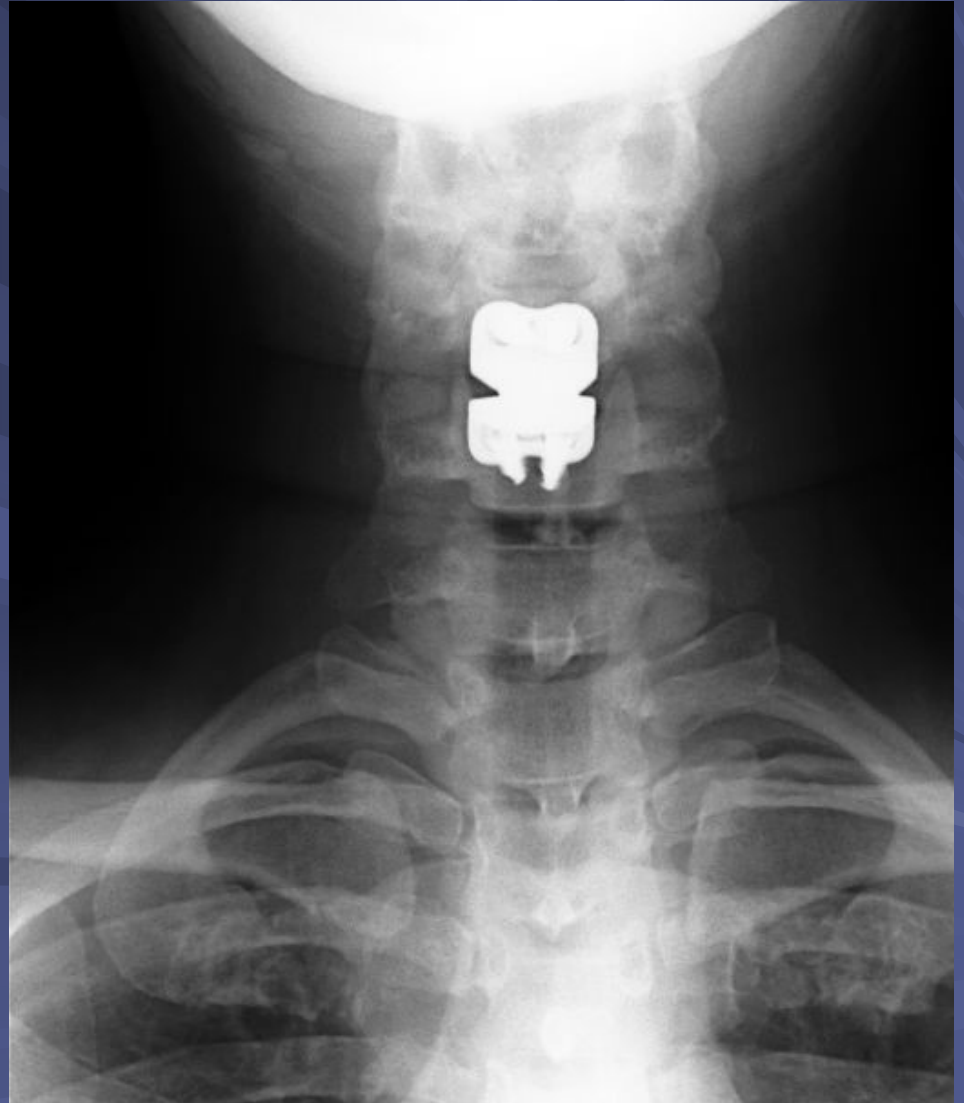
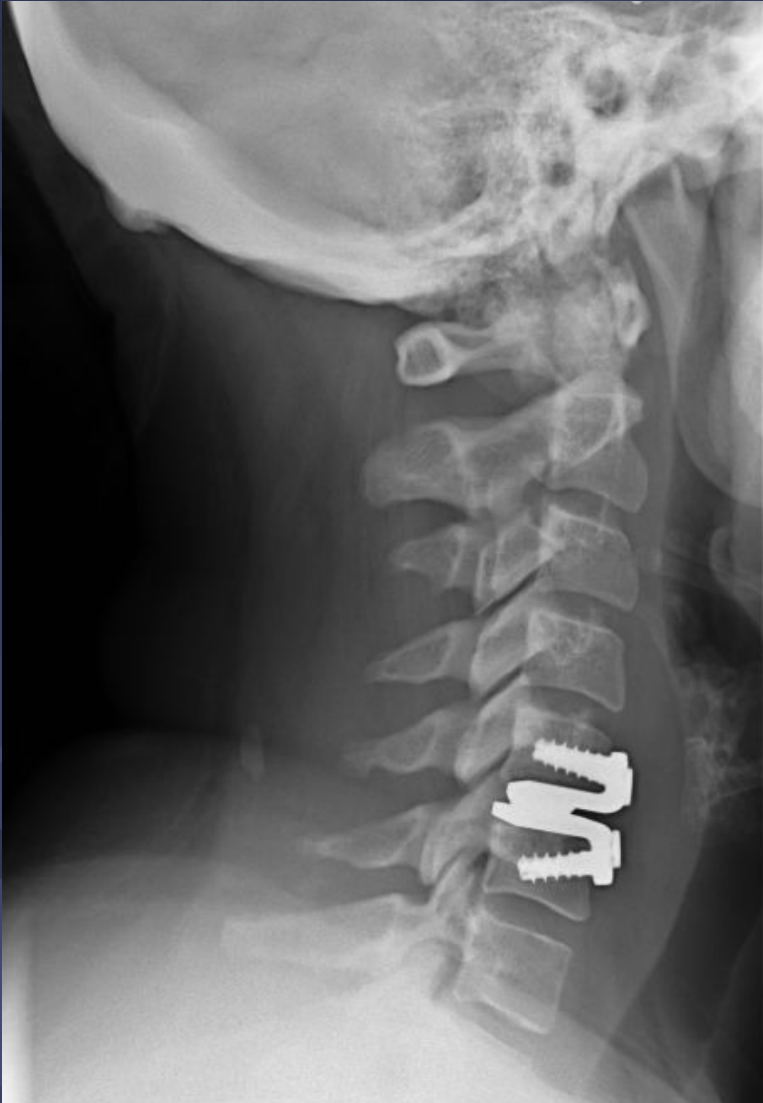Indications for Surgery

- The indications for disk replacement include degeneration at C6-7, which is not symptomatic at this point, with disk herniation at C5-6, although the adjacent segment protective aspects of TDR versus fusion are debatable. The patient is an ideal candidate in that she does have subjacent early degeneration, and the use of an artificial disk replacement might preclude her from having accelerated degeneration in the subjacent space. Clearly, she needs surgery because she has evidence of myeloradiculopathy with pain in the left arm, numbness which is ongoing, and has gliosis in her cord with significant narrowing at this level.
- Massive disc herniation C5-6 with neural foraminal stenosis.
- Severe cord compression with soft disc causing gliosis.
- Mild radiculopathy.
- Several disc degeneration C6-7.
- Failed conservative therapy.

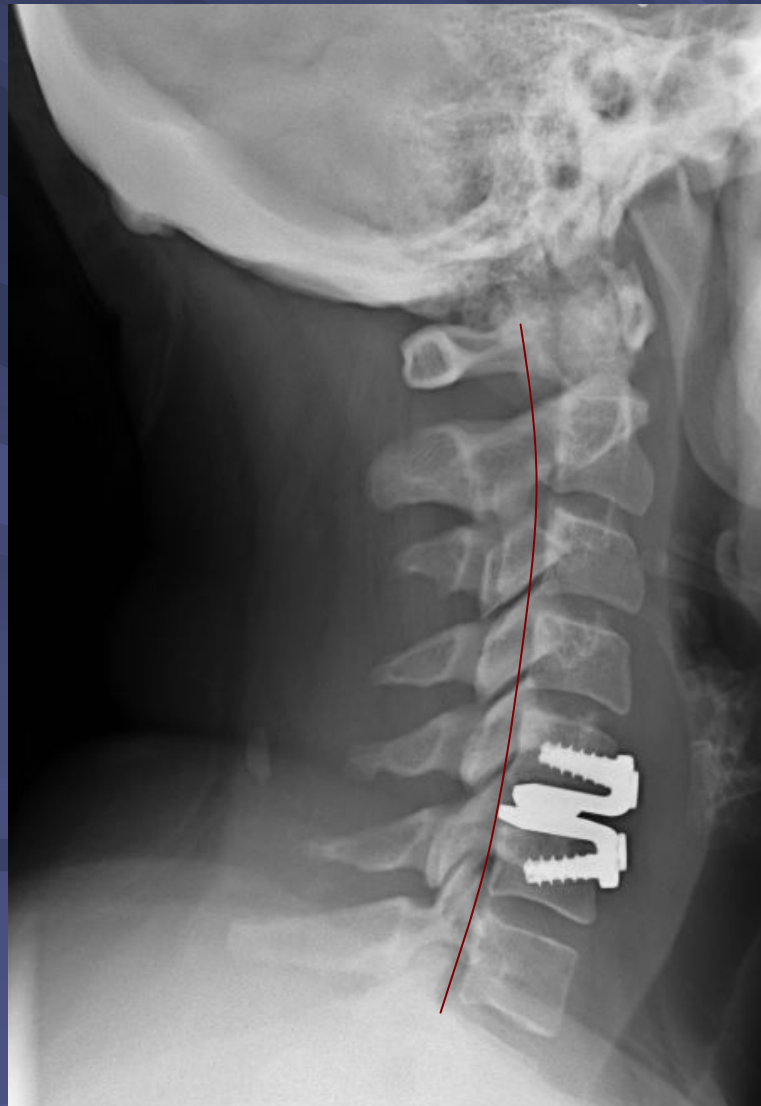
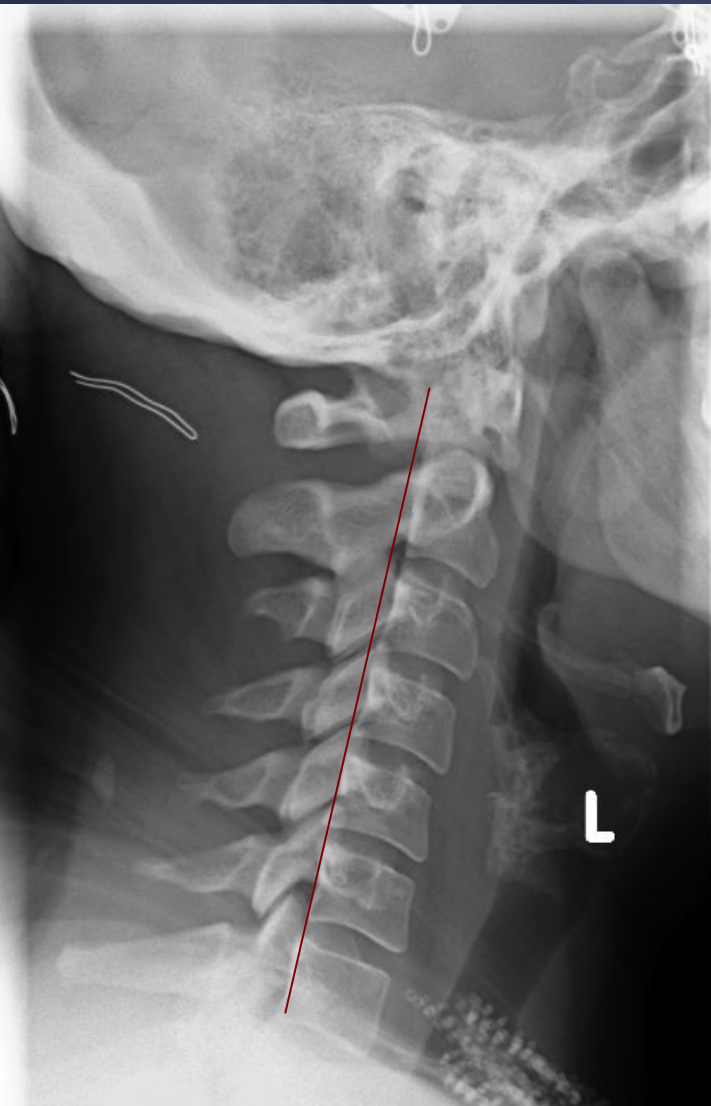
Surgical Strategy

1. Radical discectomy, C5-6, with removal of disc herniation, posterior annulus and posterior longitudinal ligament.
2. Subtotal vertebrectomy with one-third vertebrectomy C6 vertebra for removal of massive anterior osteophyte, posterior uncal vertebral osteophytes, superior and inferior in to the foramina.
3. Prestige cervical total disc replacement measuring 7 x 16 mm for replacement of herniated disc, C5-6.
4. Intraoperative SSEP's.
5. Intraoperative fluoro.

Post-Op Films



Pre-Op/Post-op Comparison



The patient's natural cervical lordosis has been restored.

The patient is doing well post-operatively.