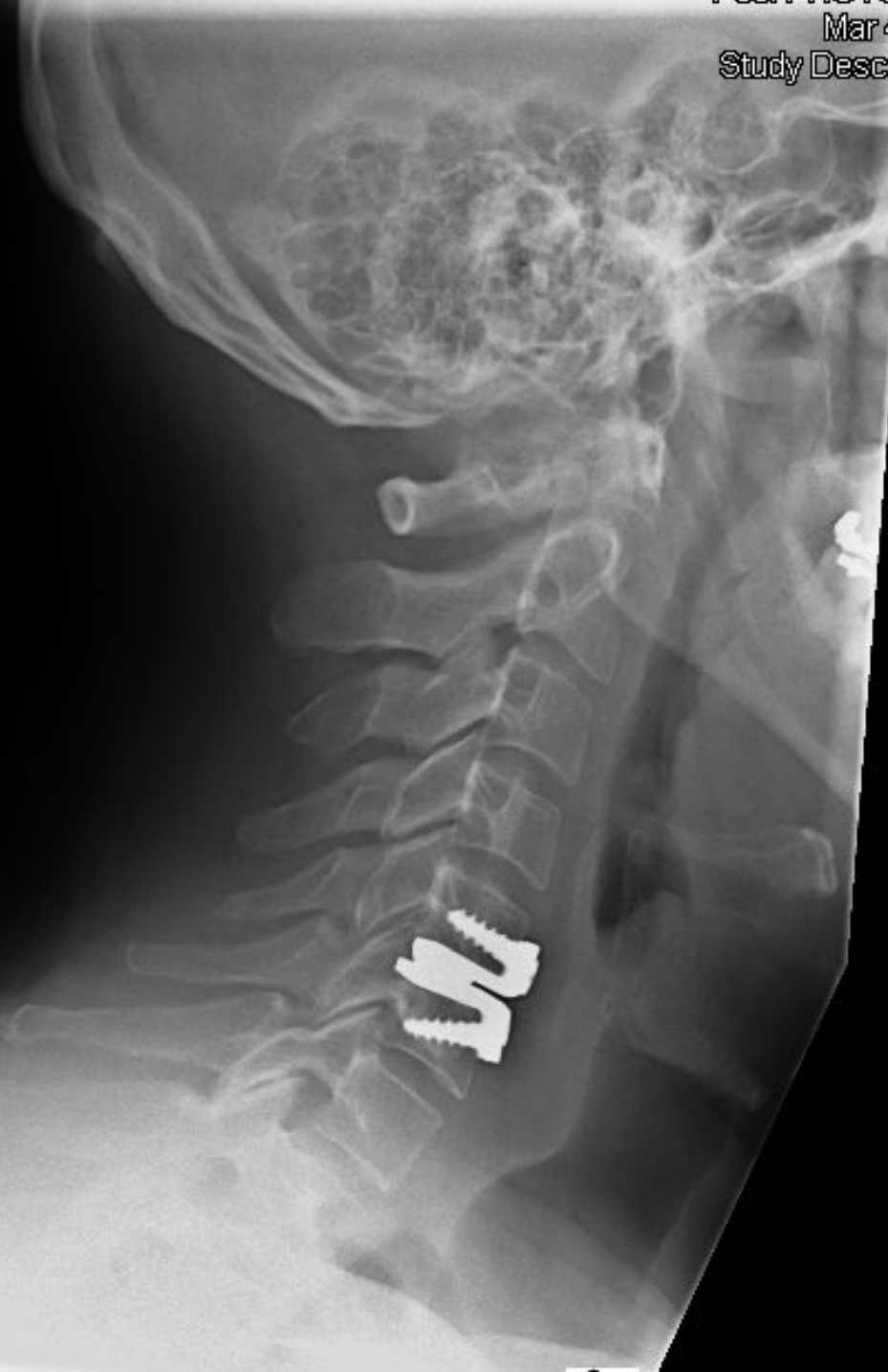



## Case Review:

### Prestige Cervical Disc Replacement at C5/6

Robert S Pashman, MD

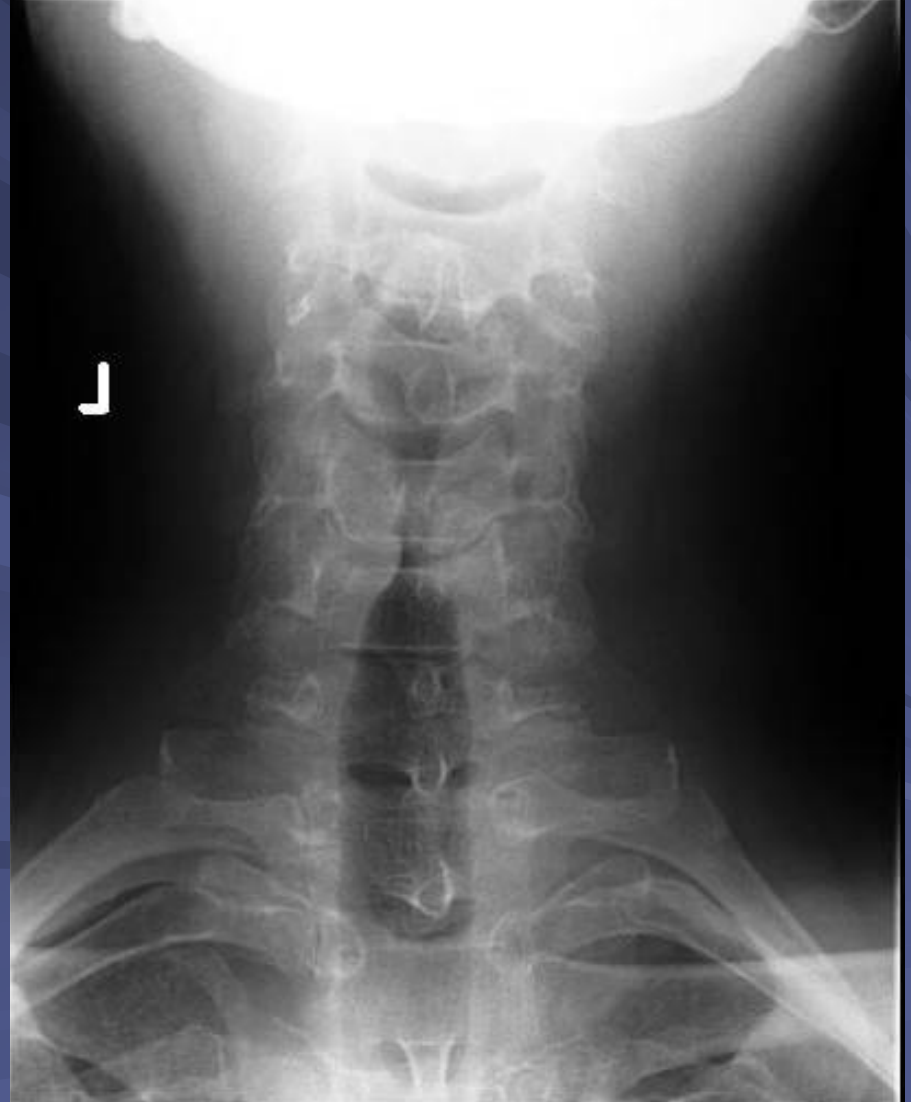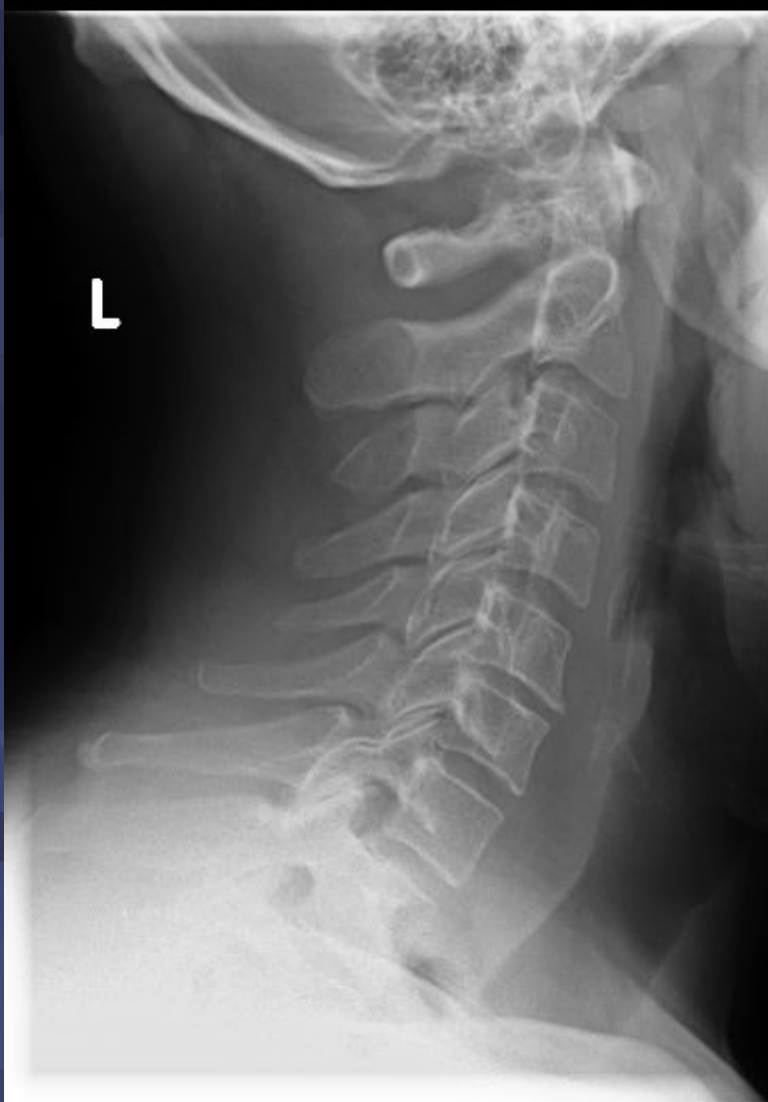Scoliosis and Spinal Deformity Surgery

[www.NeckPainExplained.com](http://www.NeckPainExplained.com)

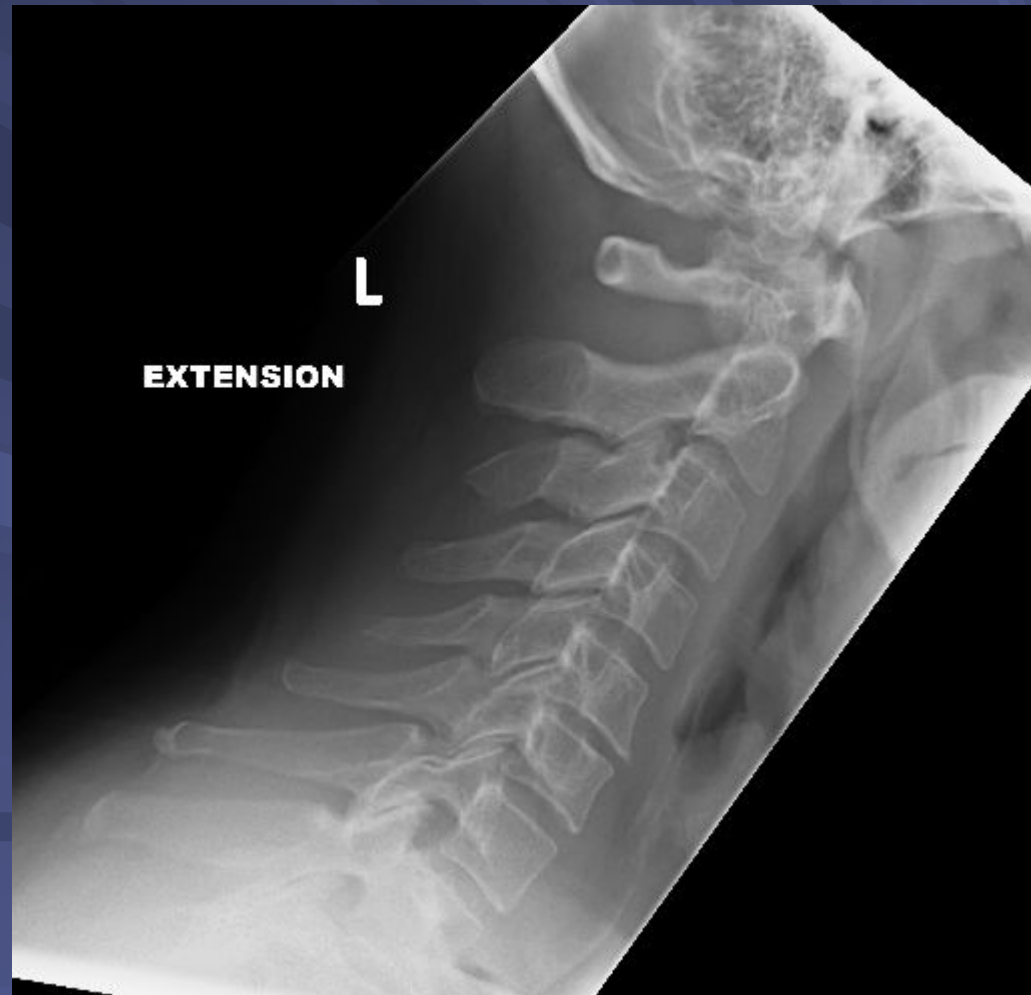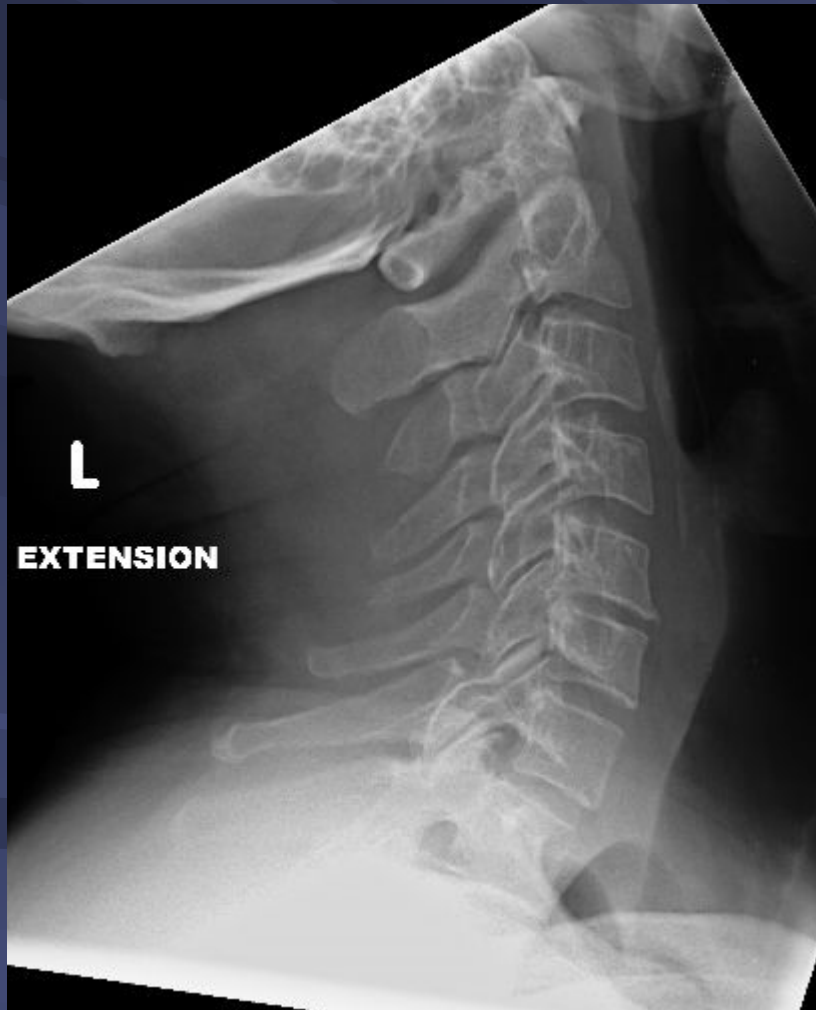# Patient History

- 42 year old male.
- Severe right shoulder and arm pain going to the thumb in the C6 distribution.
- C5/6 disc herniation found on MRI.
- Progressive pain, and arm weakness.
- The patient has a long history of sports related injuries.
- The patient has tried various holistic and conservative management treatments, including physical therapy, medicines for his neck and arm pain.

# Pre-op X-rays



# Flexion & Extension X-rays



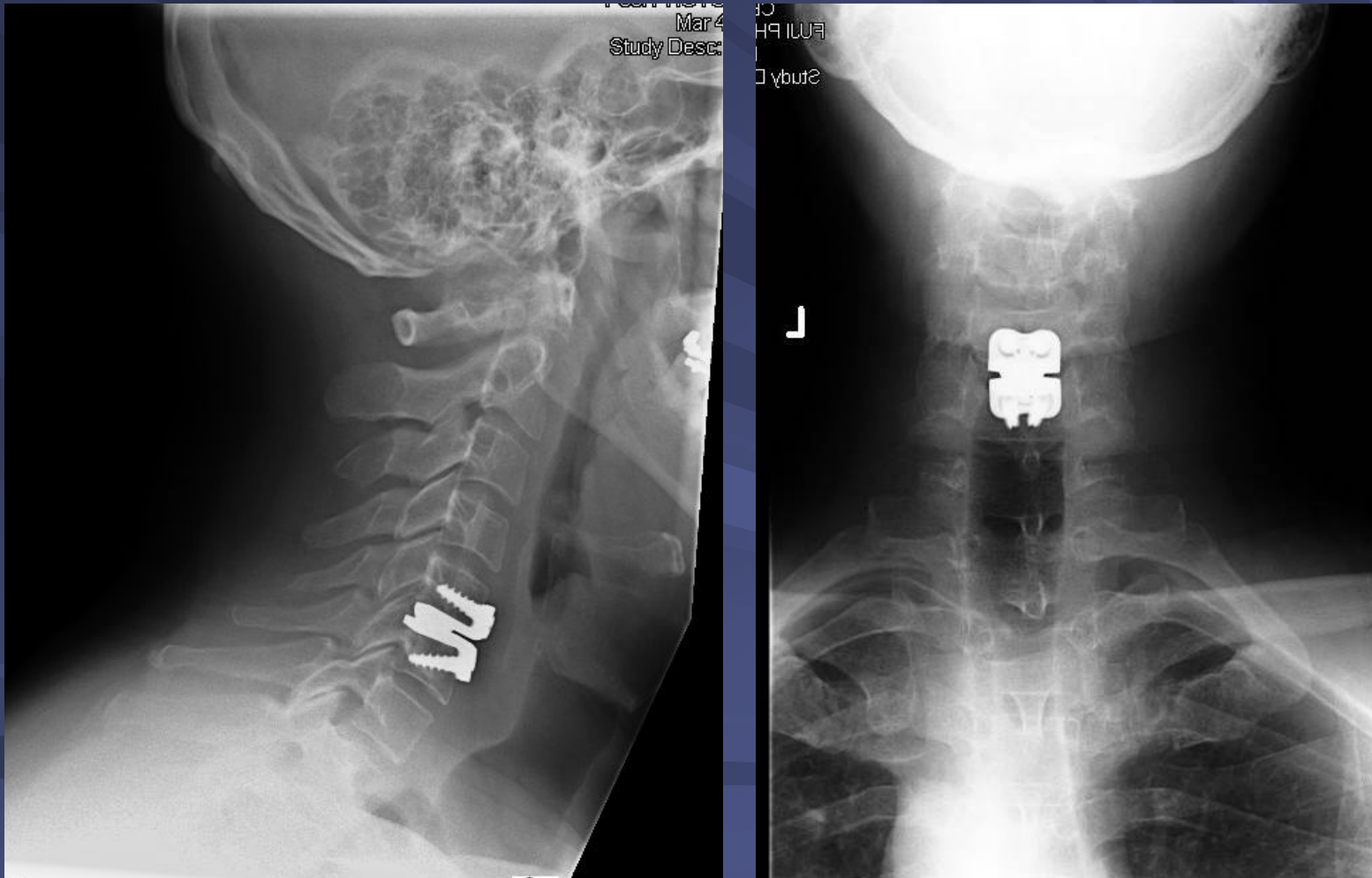
# Indications for Surgery

- Severe degenerative disk disease C5-C6.
- Right shoulder and arm pain, numb to C6 distribution, right-hand side.
- Disk degeneration and spinal cord and neural foraminal stenosis due to hard and soft disk C5-C6.
- Failed conservative therapy.
- Motor sensory deficit with biceps weakness, right arm.

# Surgical Strategy

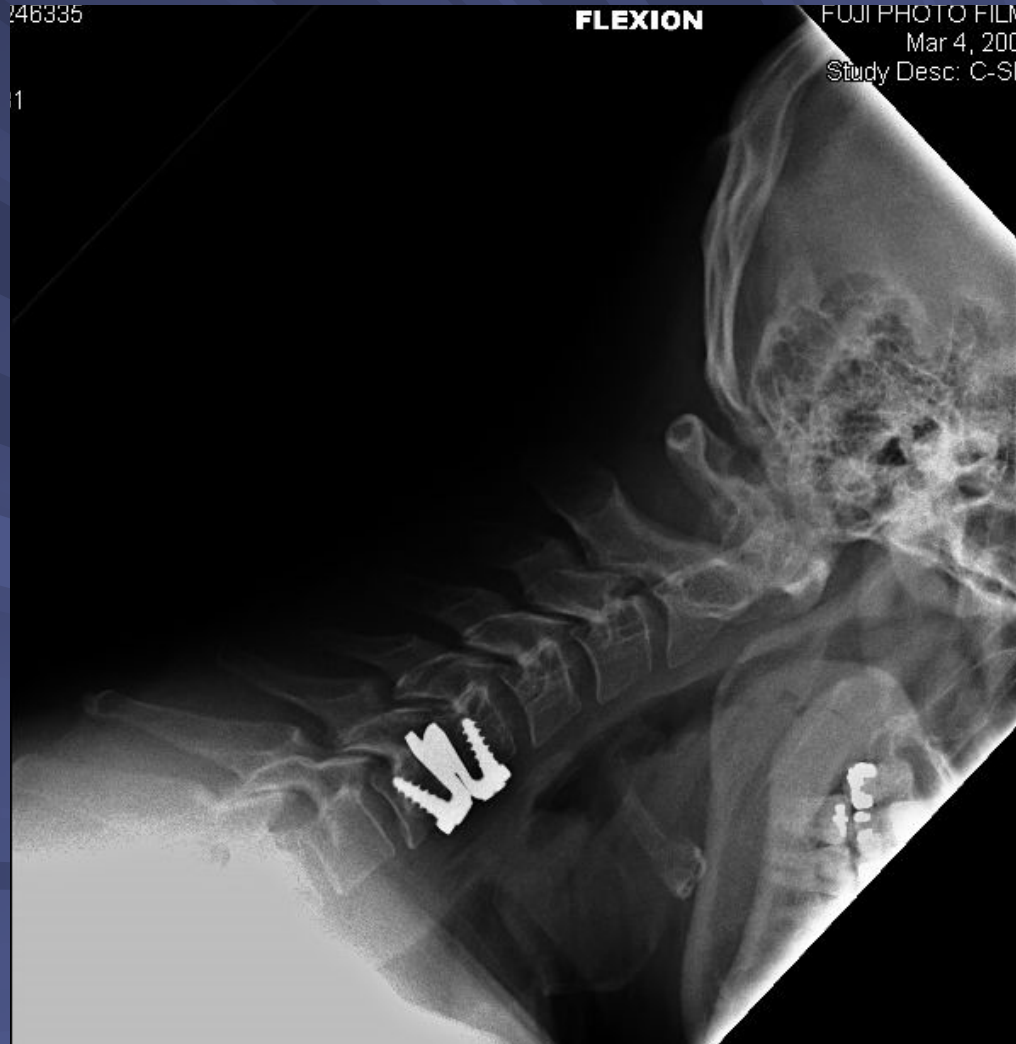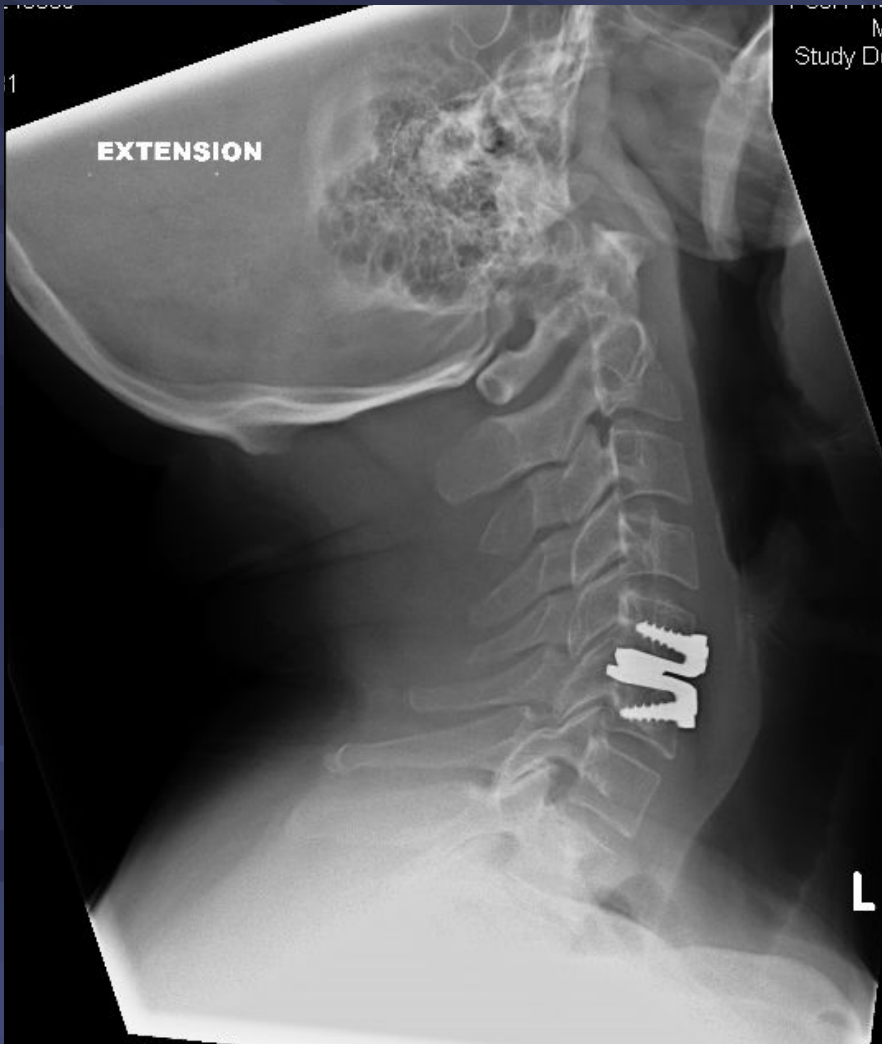- Radical diskectomy C5-C6.
- Subtotal vertebrectomy with removal of 1/3 vertebra, anterior osteophyte, posterior uncal vertebral osteophyte C5-C6 with epidural and neural foraminal decompression.
- Interbody device C5-C6 with a Prestige 7 x 16 mm articulated total disk replacement.
- Intraoperative somatosensory evoked potentials.
- Intraoperative fluoroscopy.

# Post-Op Films



The patient has some residual neck pain, but has been released for full activity and may take anti-inflammatory medication as needed.

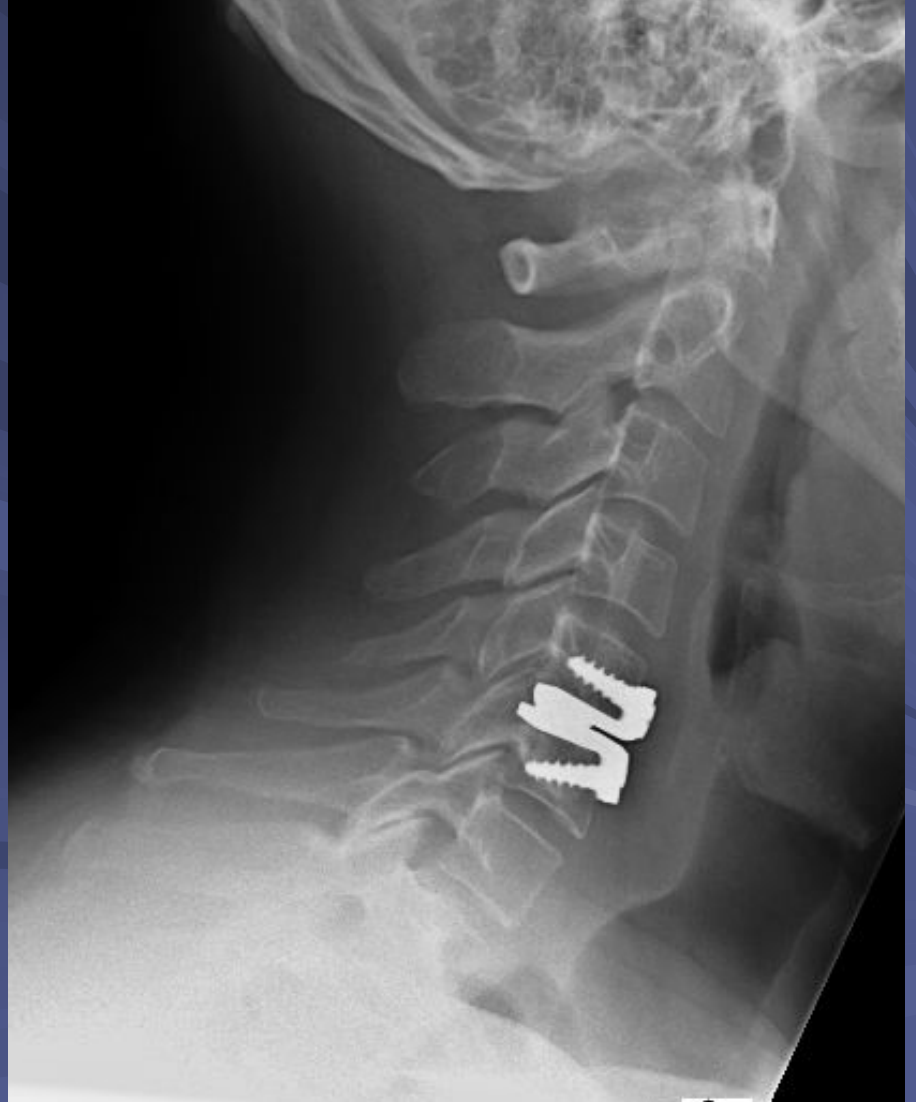# Post-Op Films



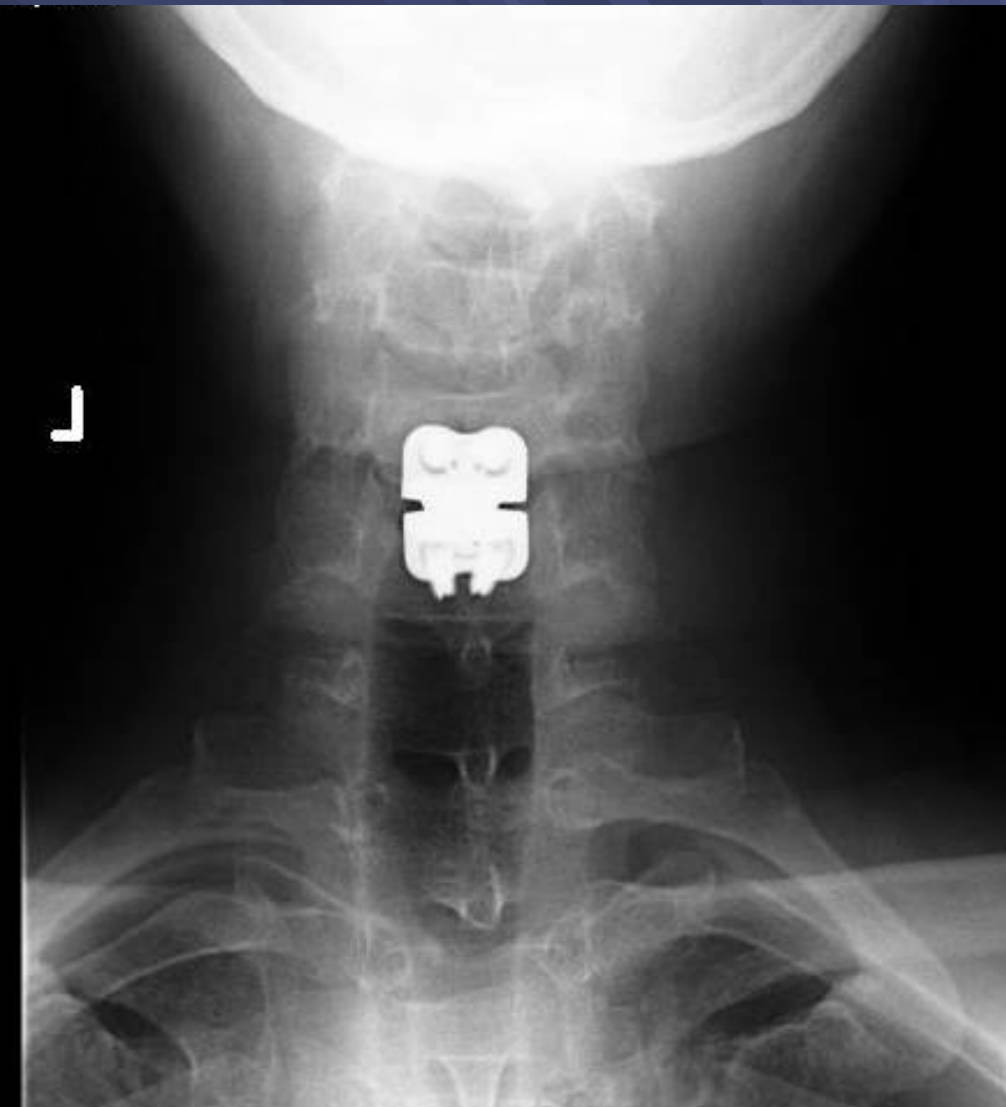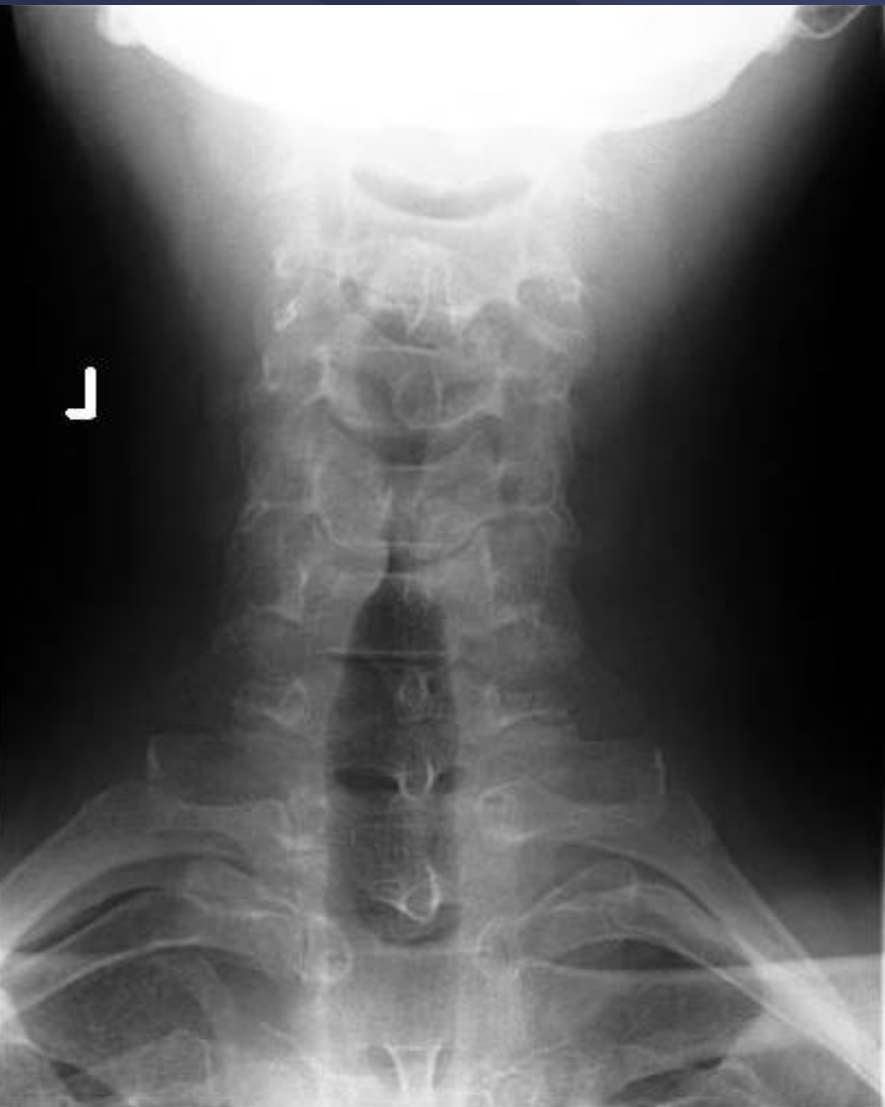246335  
M  
Study Desc: C-S

FUJI PHOTO FILM  
Mar 4, 200  
Study Desc: C-S

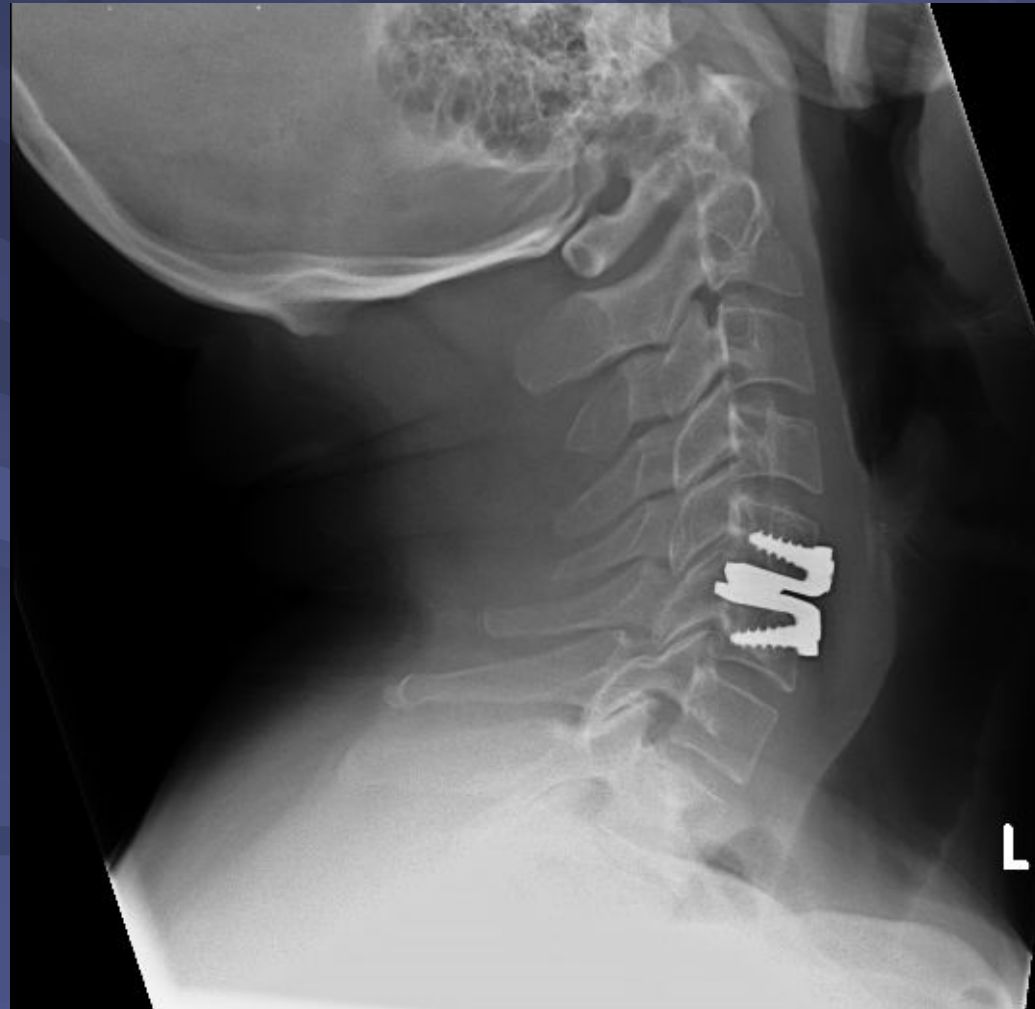
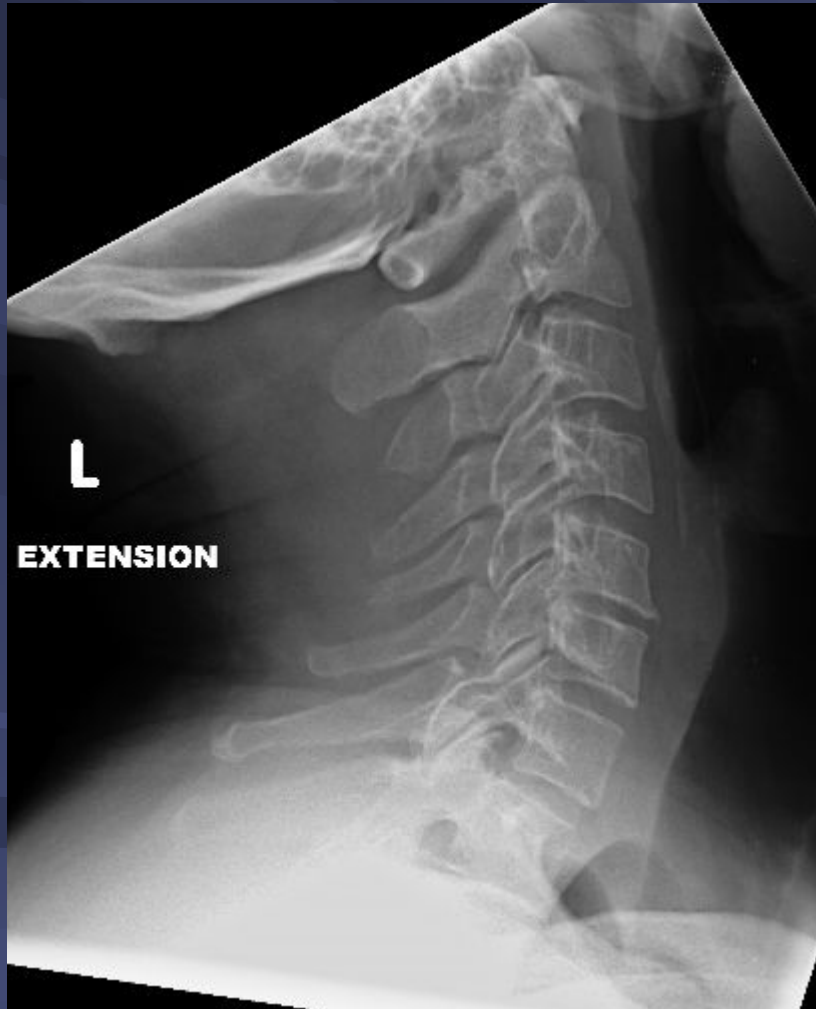# Pre-Op/Post-op Comparison



# Pre-Op/Post-op Comparison



# Pre-Op/Post-op Comparison



# Pre-Op/Post-op Comparison

