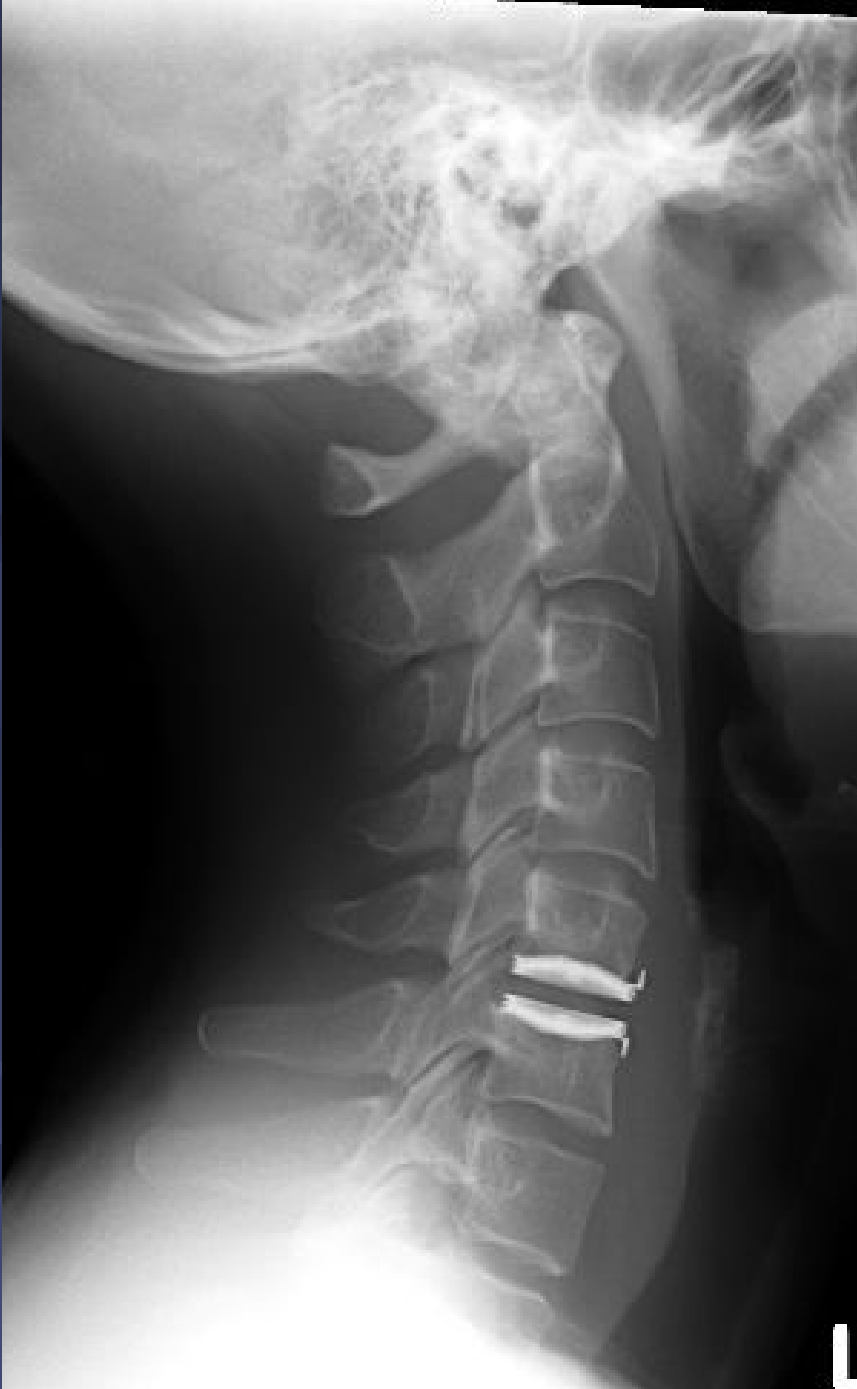



## Case Review: Bryan Artificial Cervical Disc

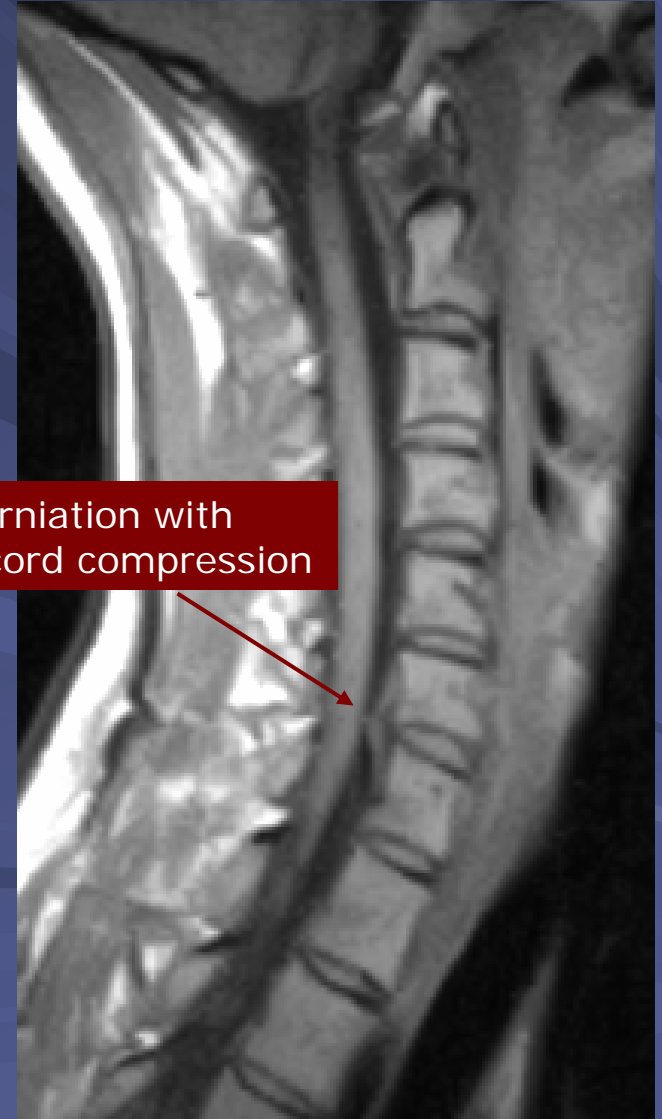
Robert S Pashman, MD

Scoliosis and Spinal Deformity Surgery  
[www.NeckPainExplained.com](http://www.NeckPainExplained.com)

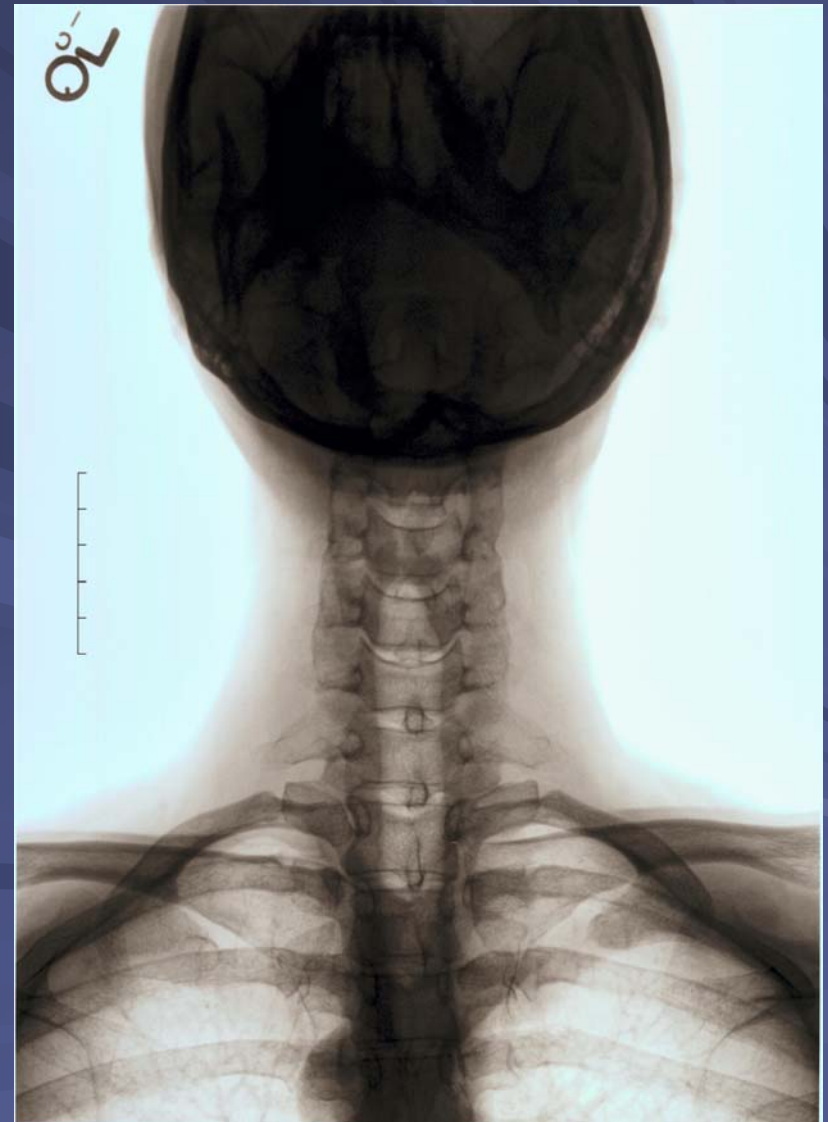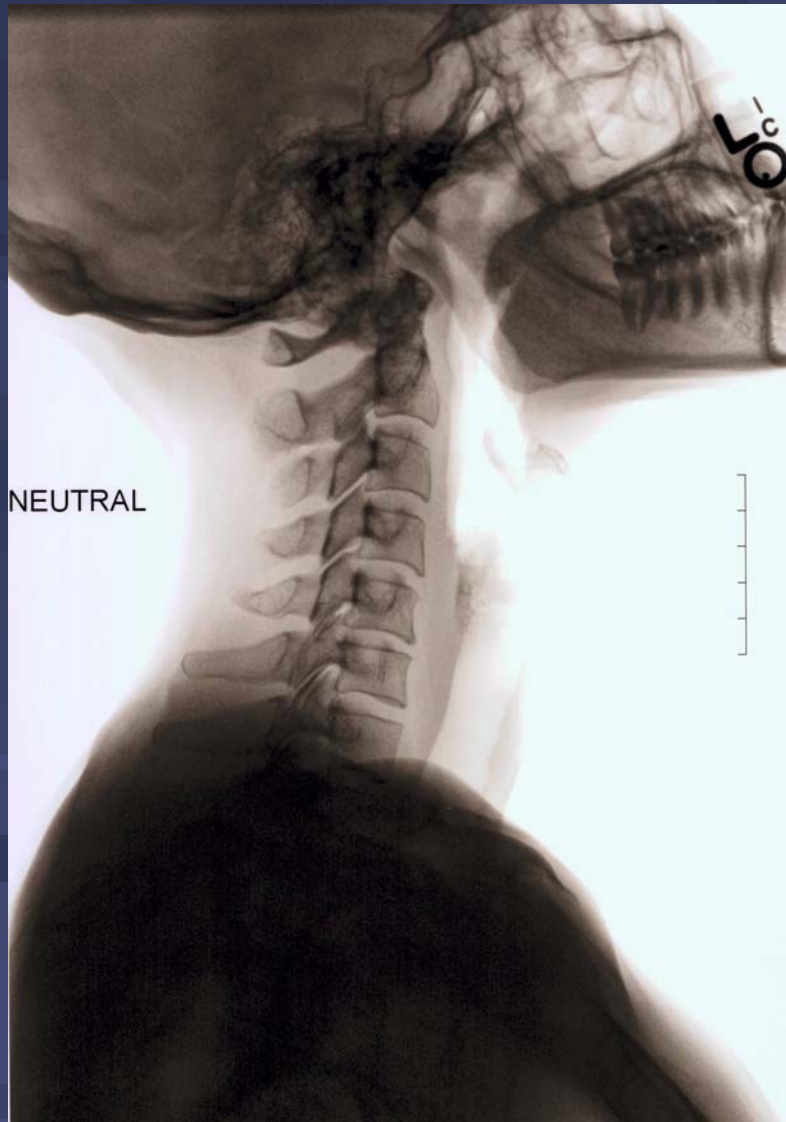
# Patient History

- 40-year-old female
- Patient has arm pain and neck pain
- Failed conservative therapy
- MRI shows severe nerve compression, cord compression due to disc herniation C5-6.

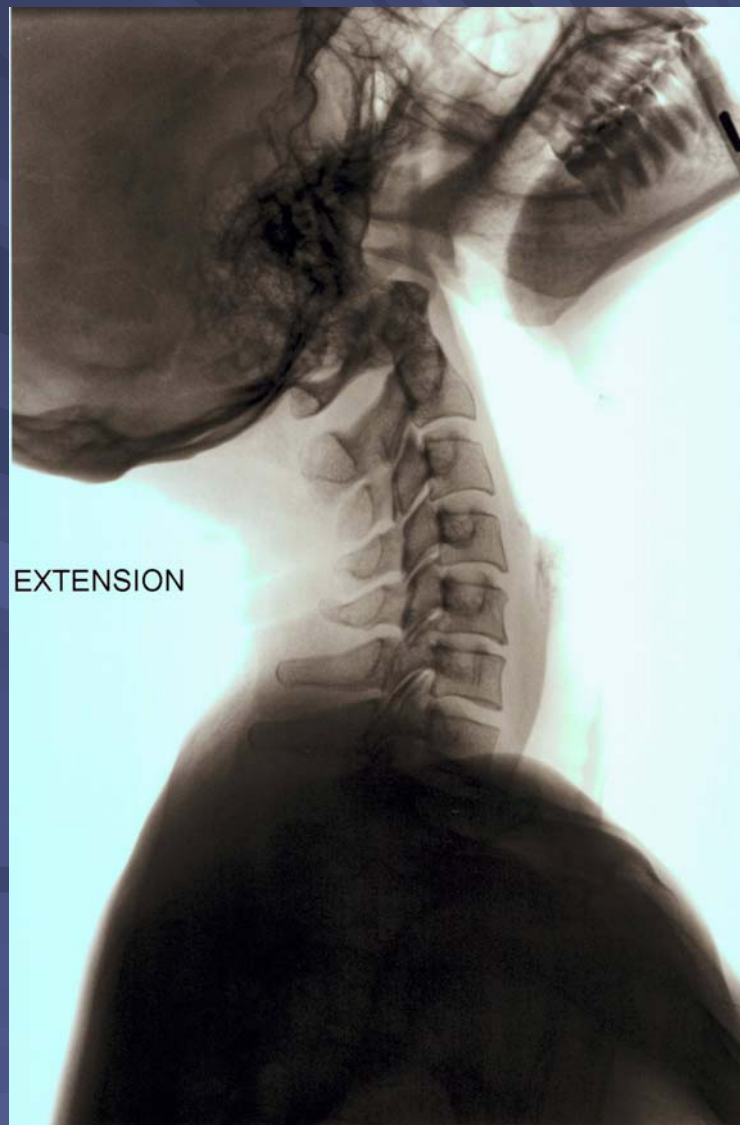
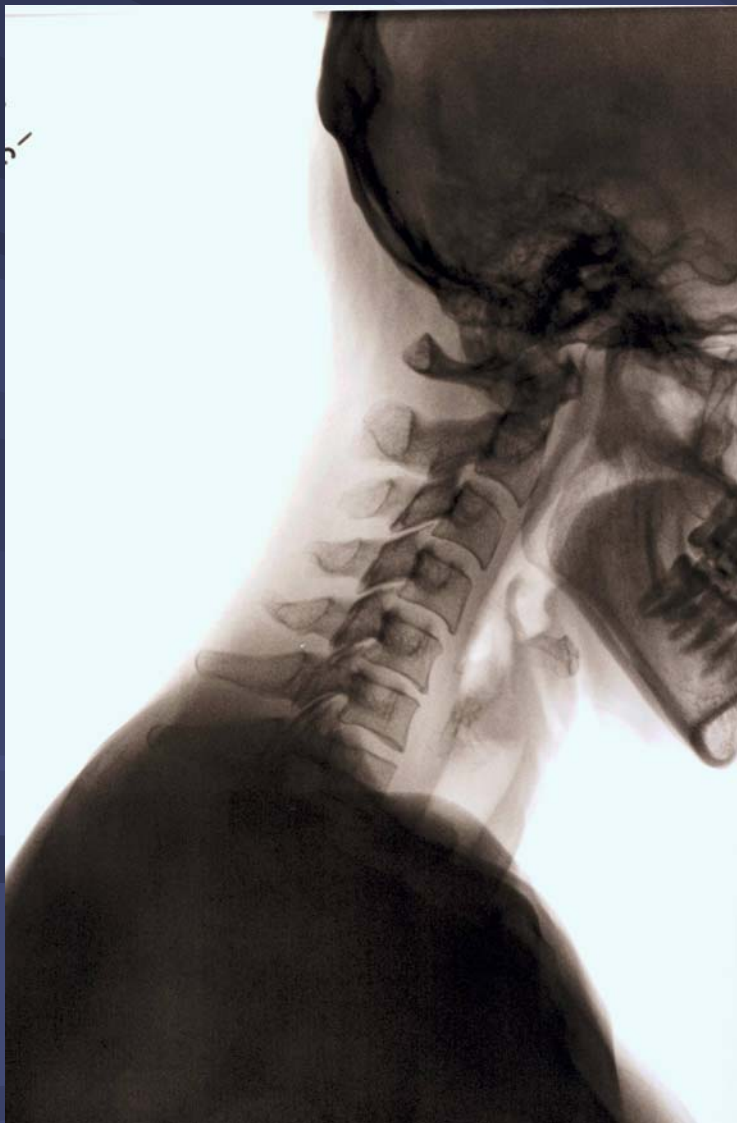Disc herniation with spinal cord compression



# Pre-op X-rays

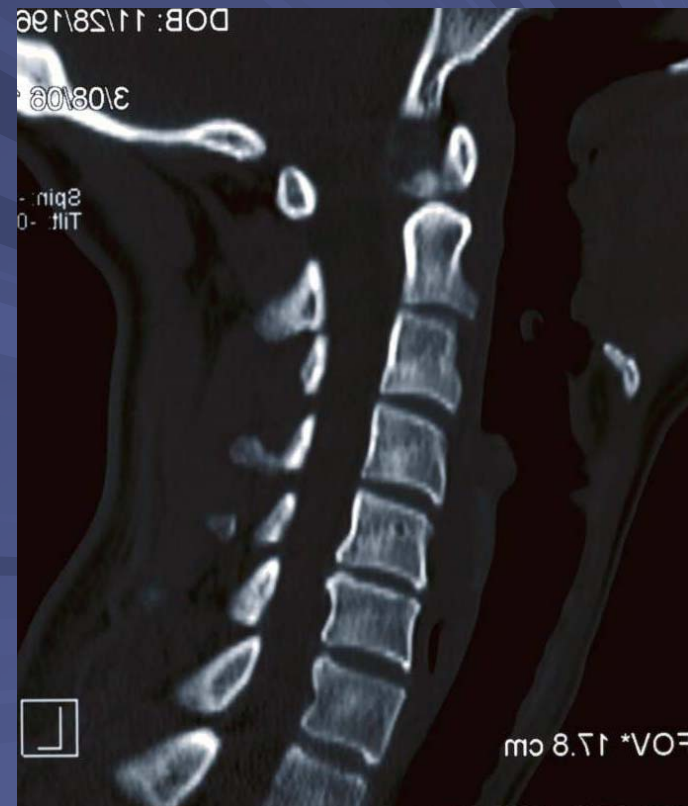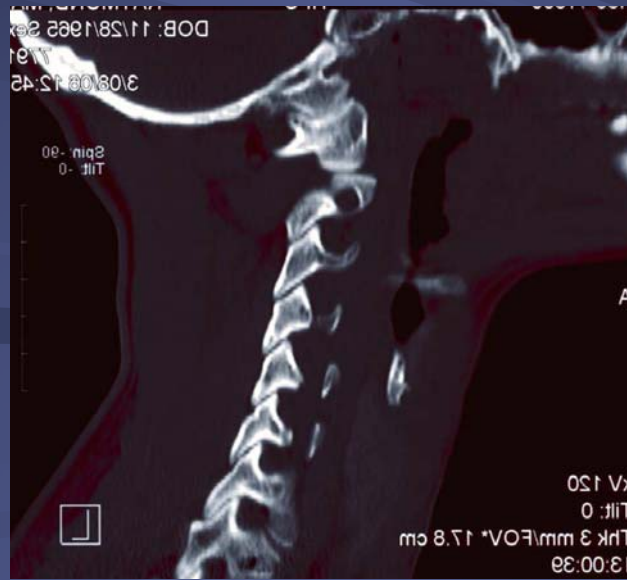
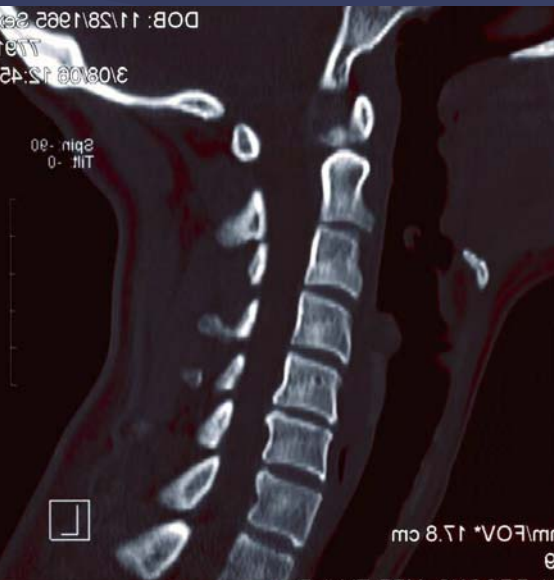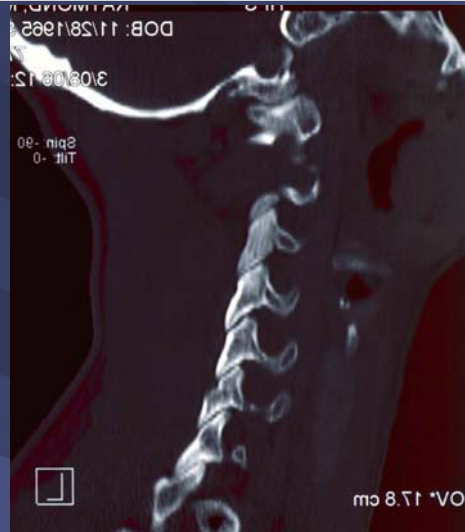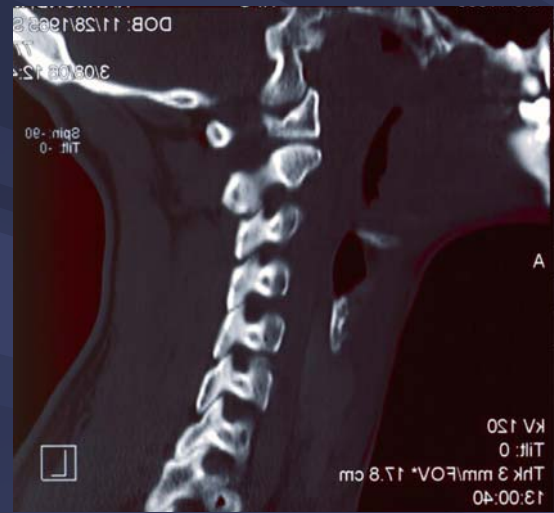


# Flexion/Extension X-rays



# Pre-OP CT Scan

A CT Scan is performed to check the facet joints and to pick the appropriate size artificial disc prior to surgery.



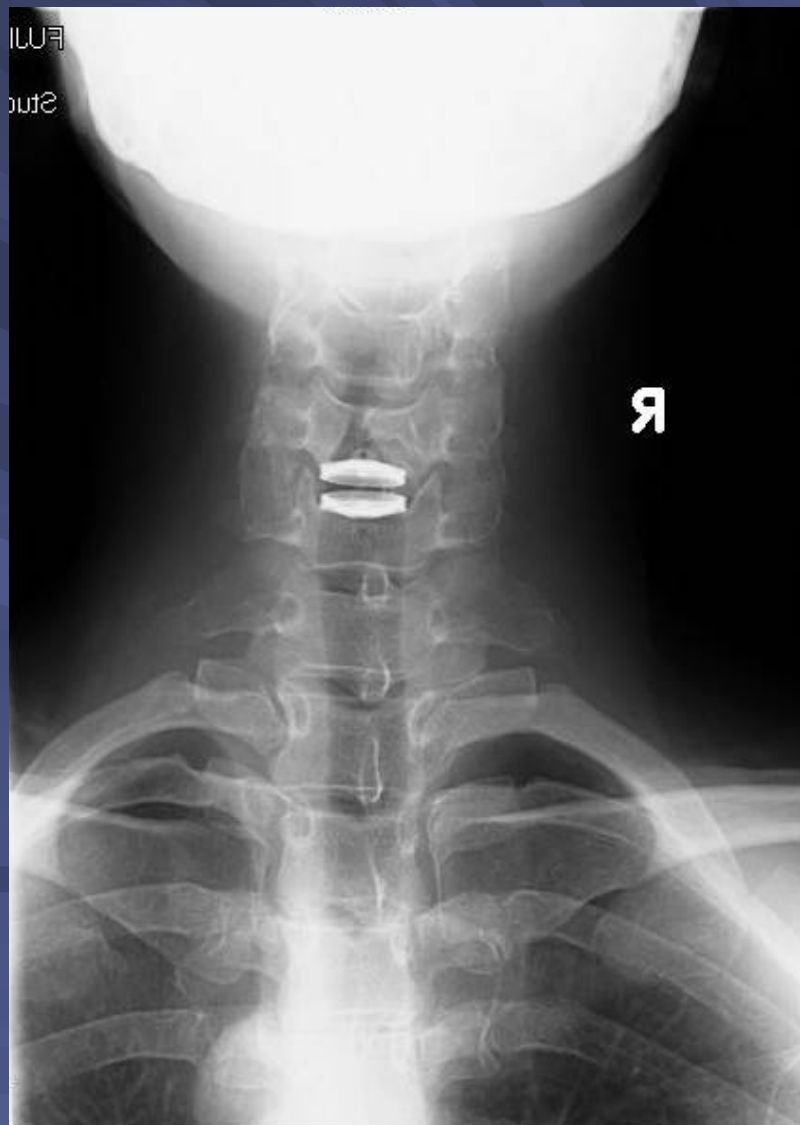
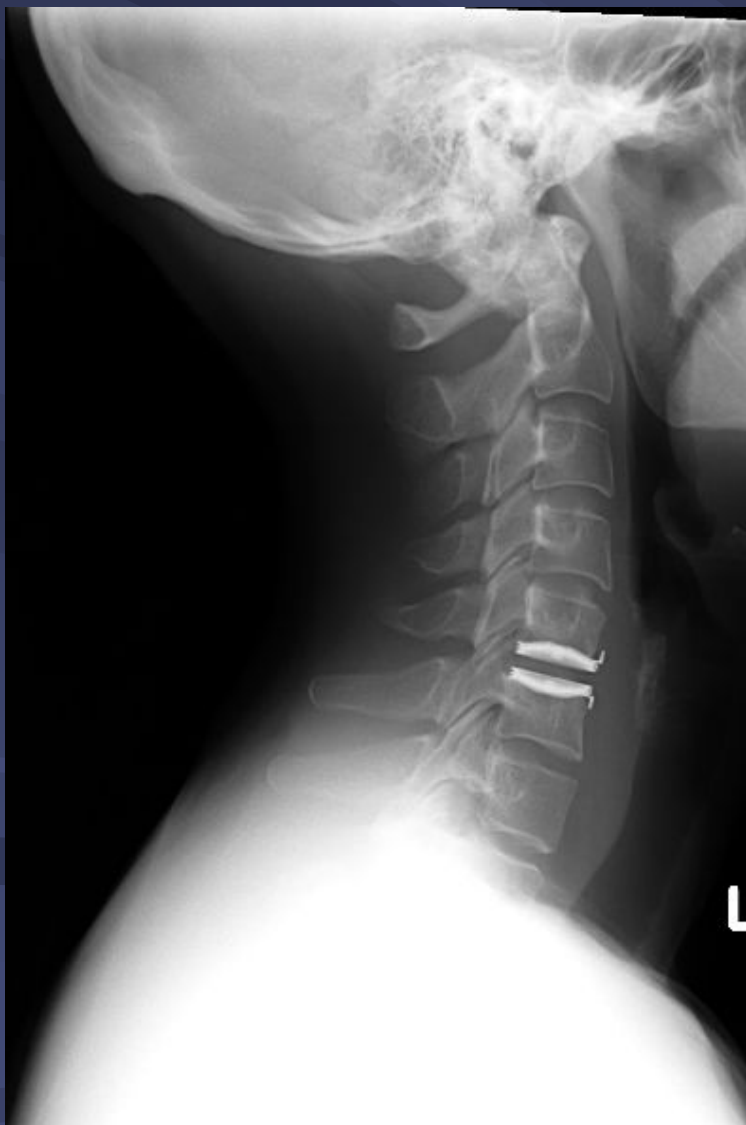# Indications for Surgery

- Degenerative joint disease
- Disc herniation at C5-6.
- Spinal cord compression
- Radiculopathy of C6 distribution in arms bilaterally.
- Failure of conservative therapy with neck and arm pain.

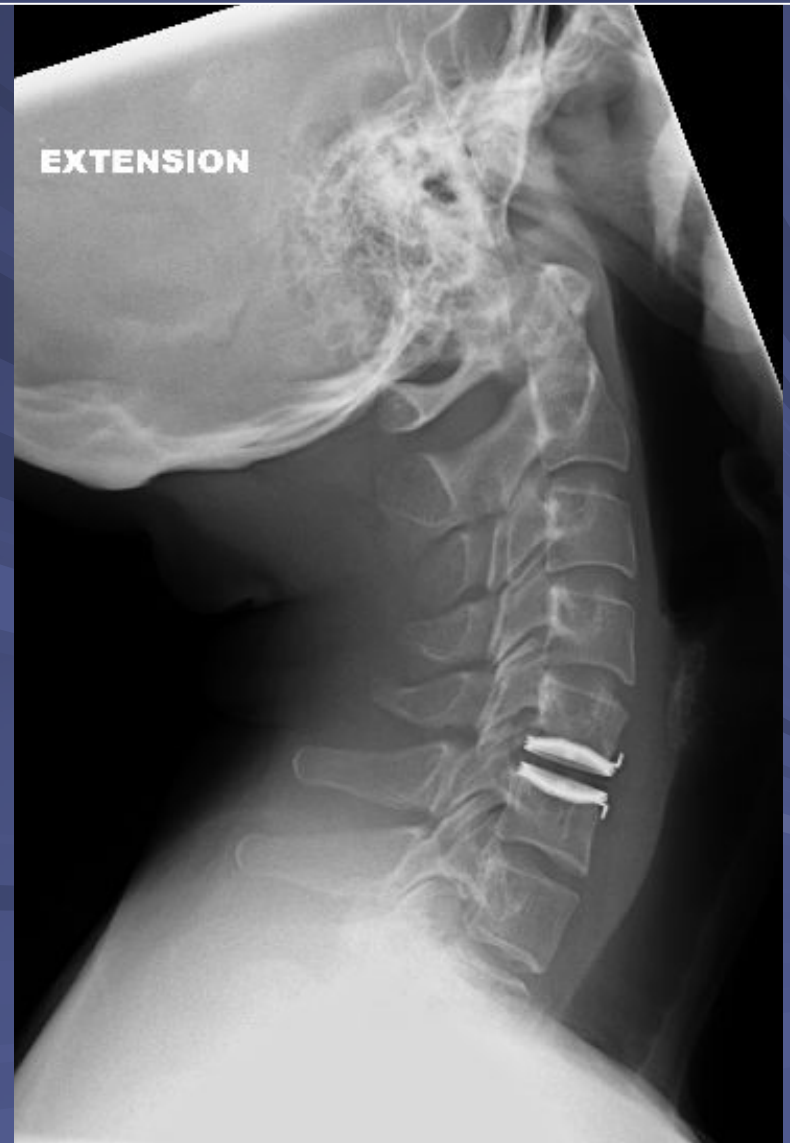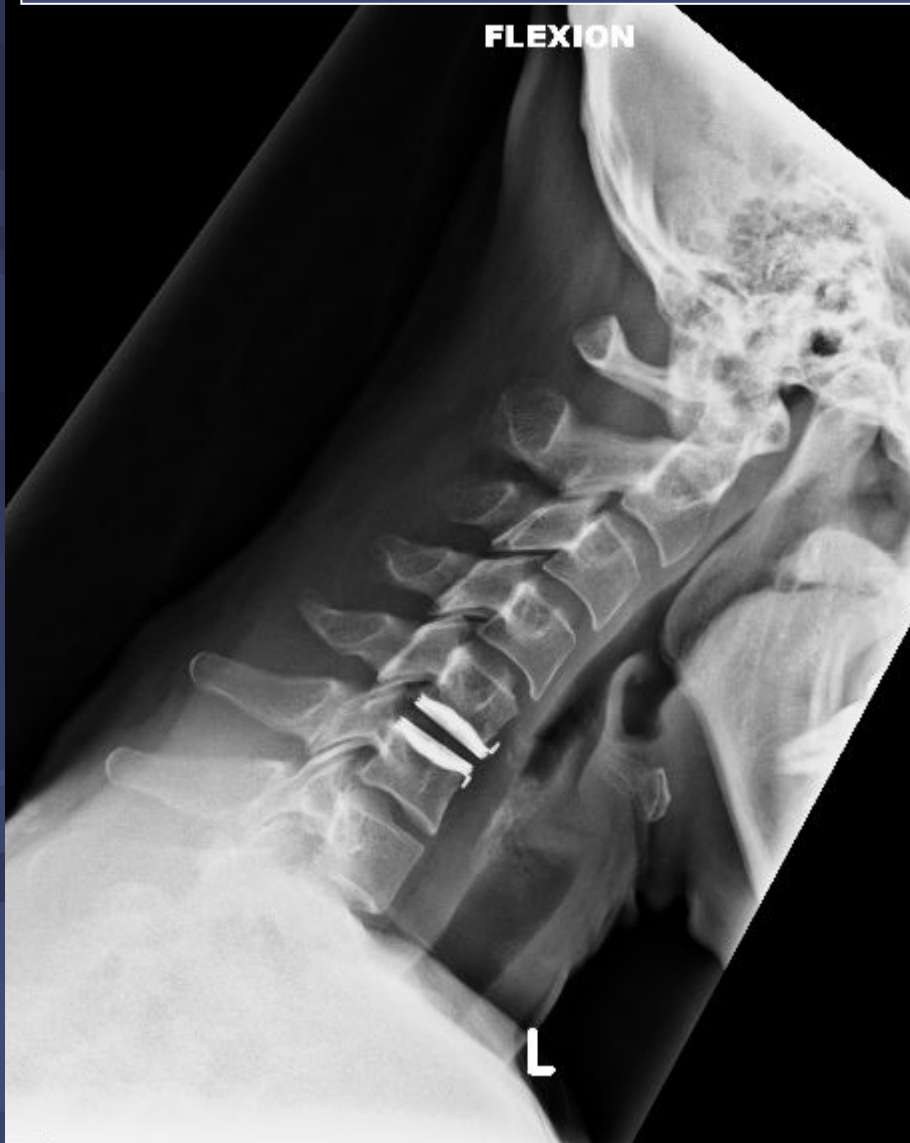# Surgical Strategy

- Radically anterior cervical discectomy for removal of spinal cord decompression with microscope C5-6.
- Bilateral nerve foraminotomy C5-6 under the microscope.
- Anterior interbody device placement with Bryan cervical disc arthroplasty under Investigational Device Exemption, C5-6 measuring 16 mm.
- Intraoperative somatosensory evoked potential.
- Intraoperative fluoroscopy.

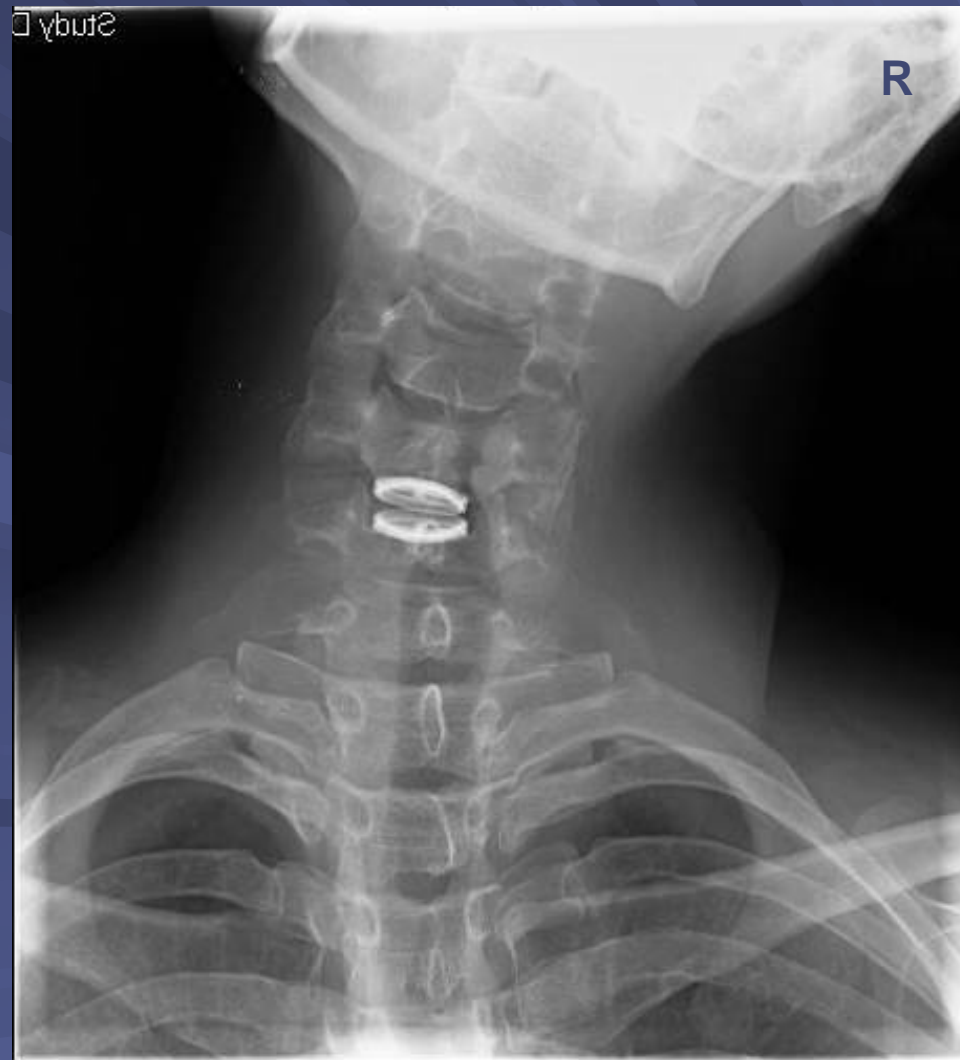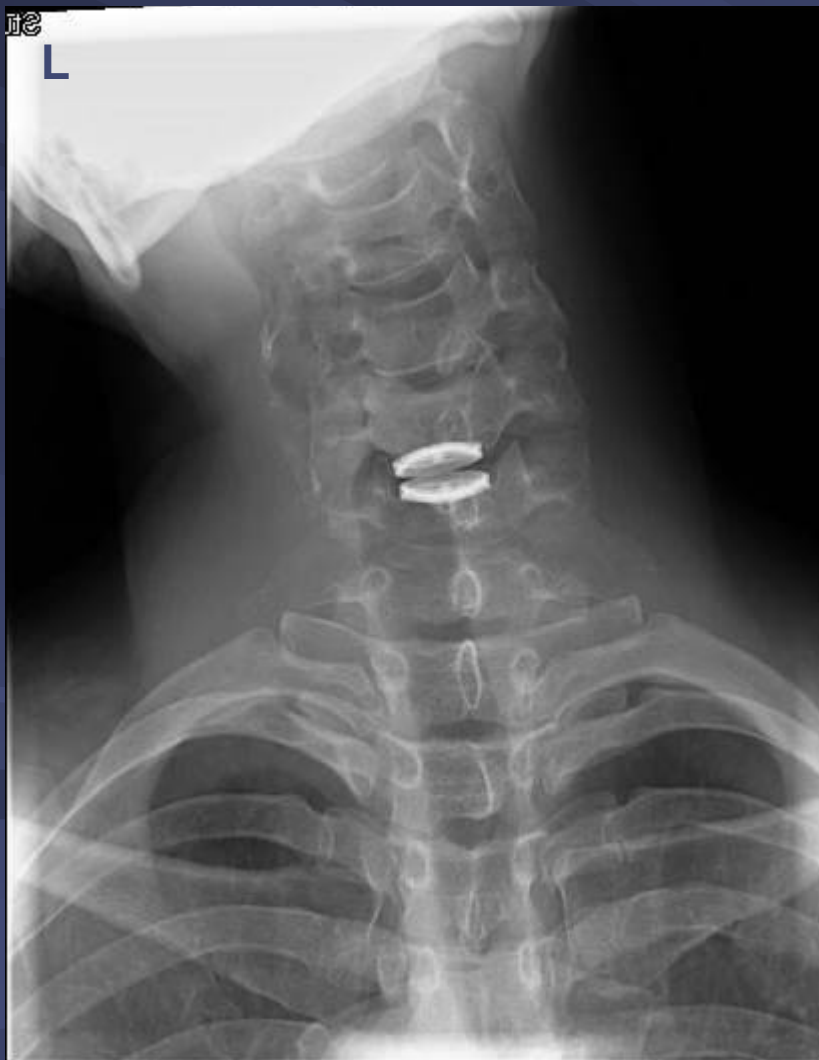# Post-Op Films



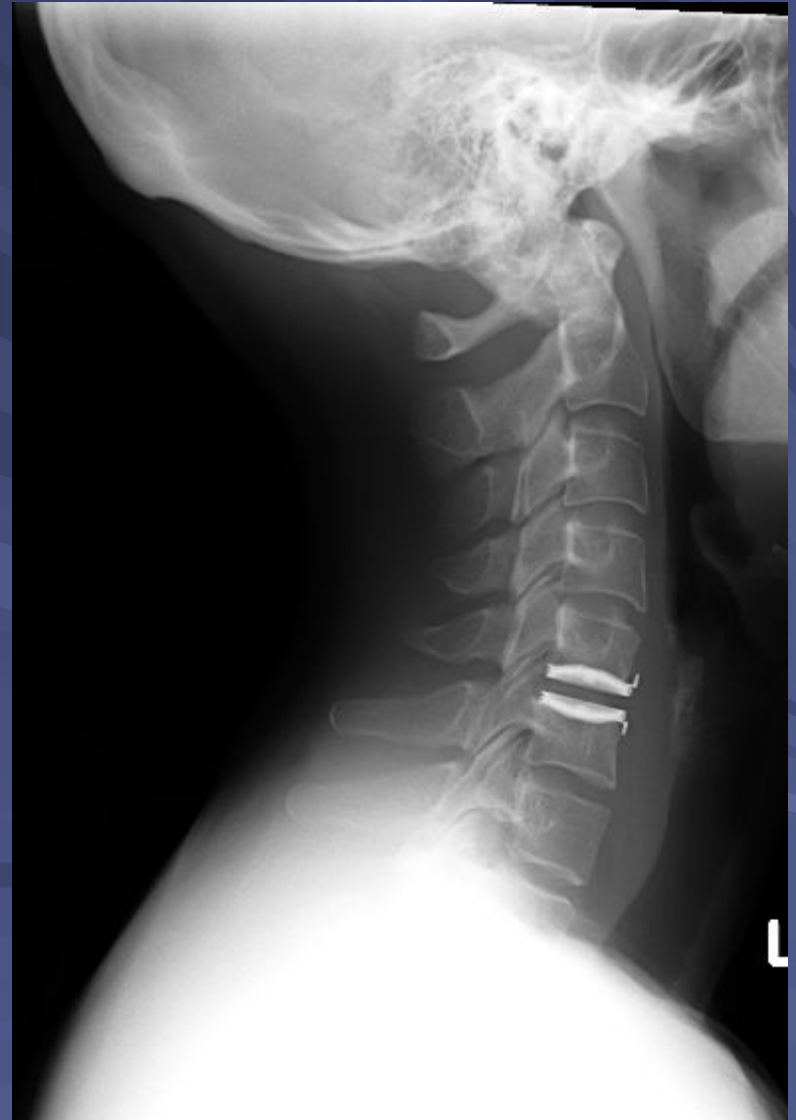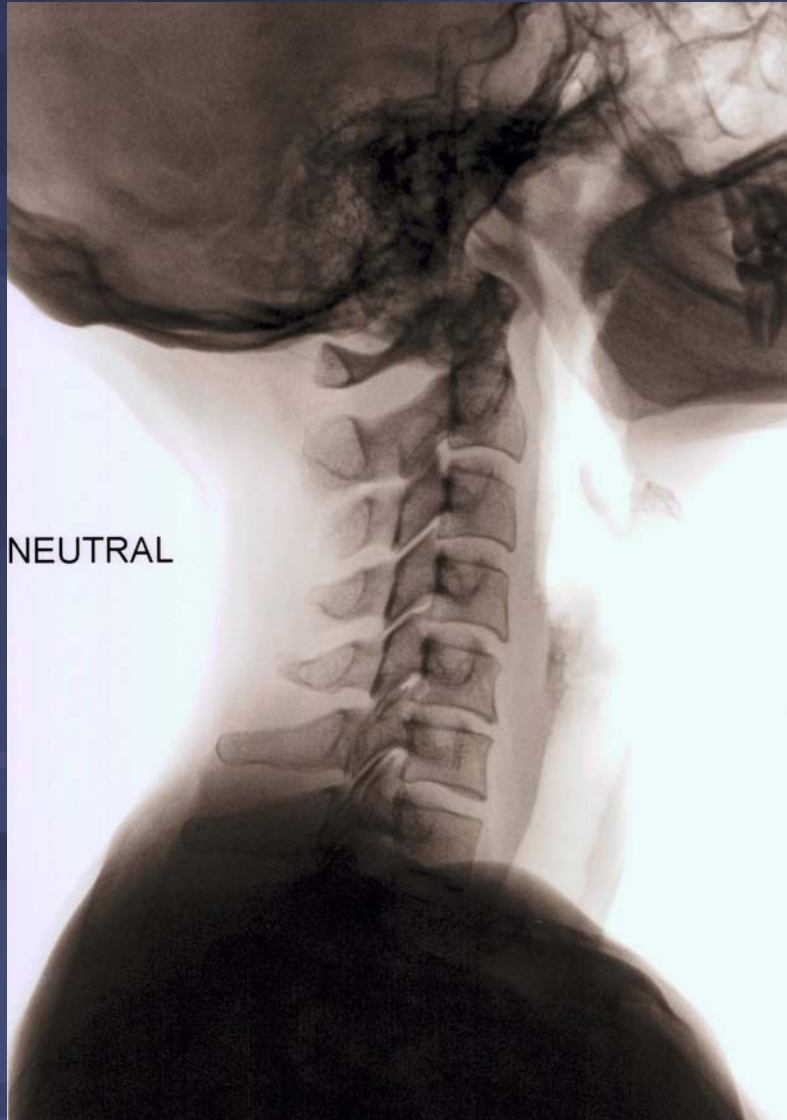
# Post-Op Flexion & Extension Films



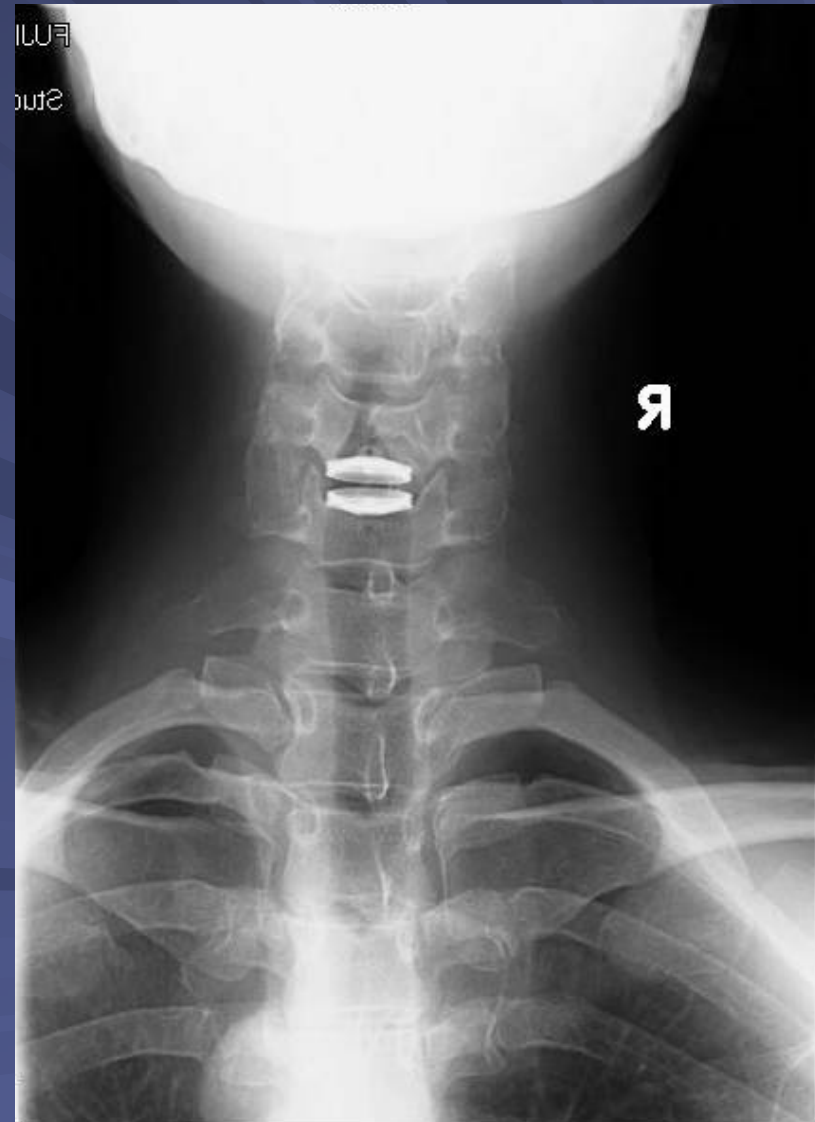
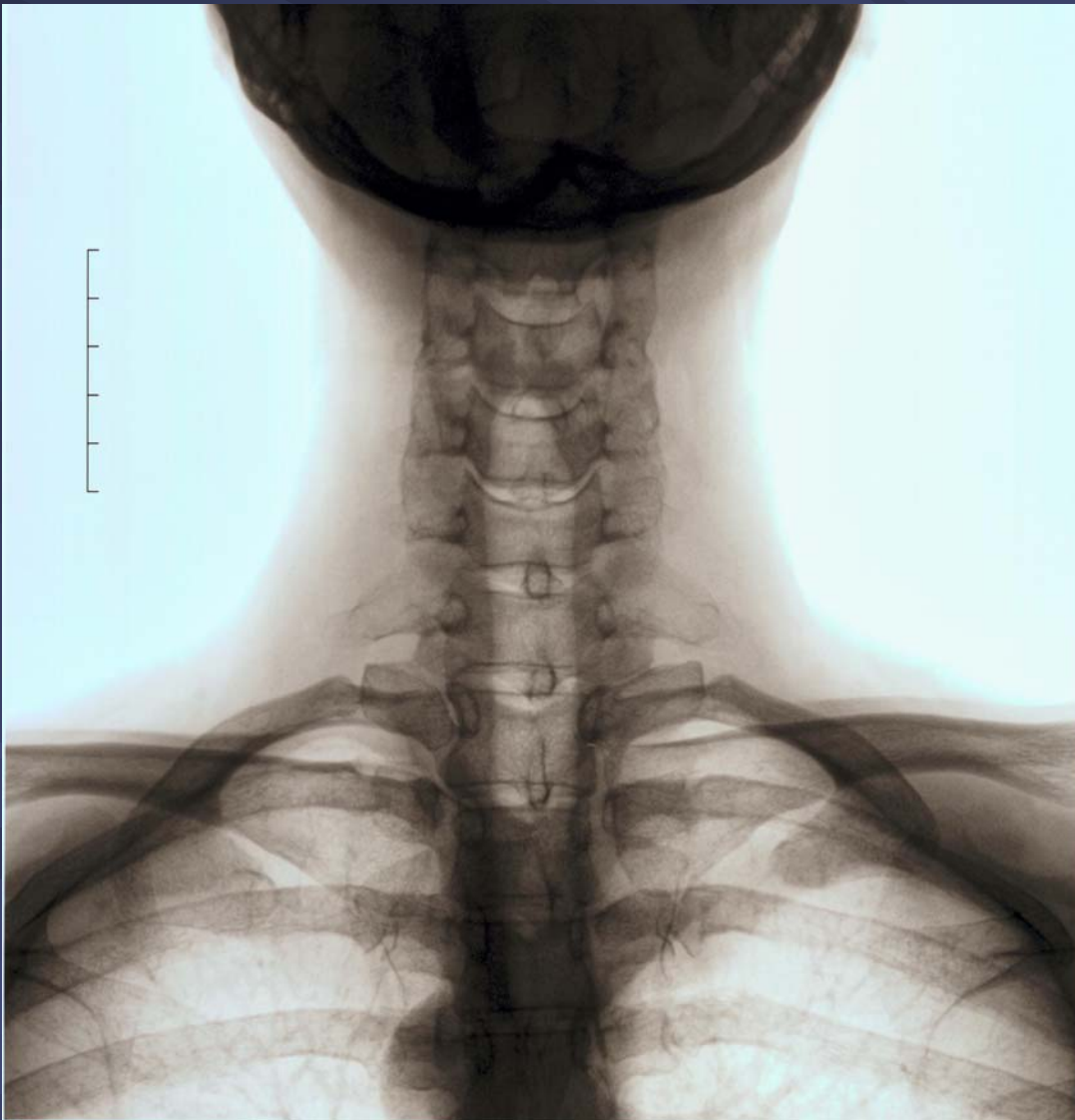# Post-Op Films



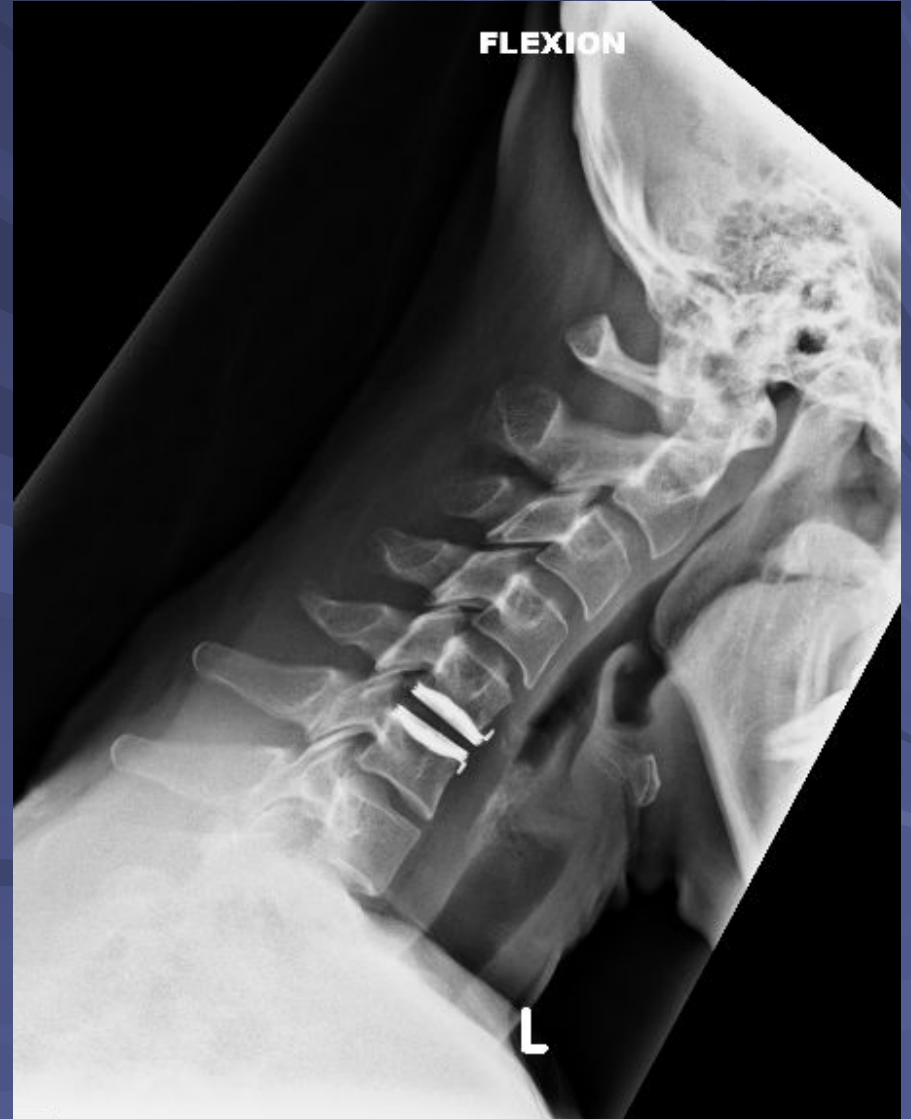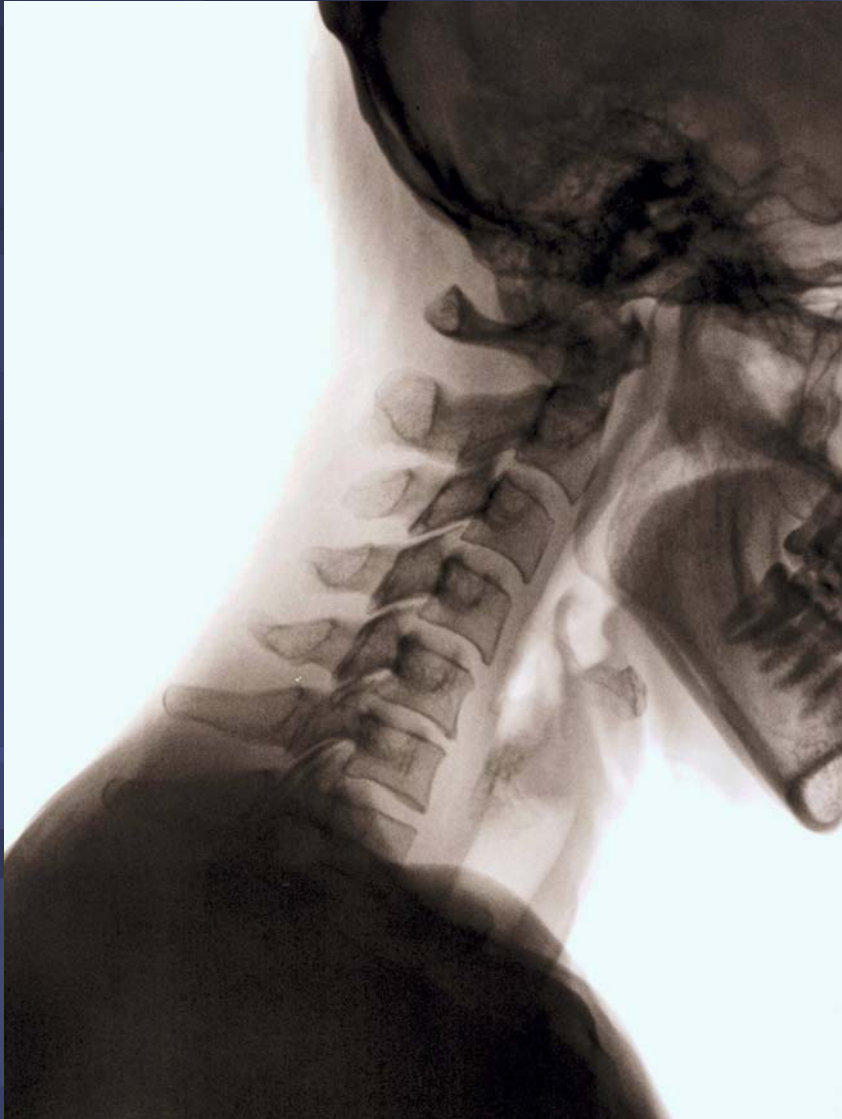# Pre-Op/Post-op Comparison



# Pre-Op/Post-op Comparison



# Pre-Op/Post-op Comparison



# Pre-Op/Post-op Comparison

